

CURSO DE ELECTROCARDIOGRAFÍA BÁSICA

Interpretación del E.C.G.

Dr. F. Richard

Interpretación del E.C.G.

Algoritmo de lectura

- ✓ Frecuencia cardíaca
- ✓ Ritmo
 - ✓ Sinusal
 - ✓ Arritmia
- ✓ Medir intervalos
 - ✓ PR
 - ✓ Normal
 - ✓ Corto: Preexcitación
 - ✓ Largo: Bloqueo AV
 - ✓ QRS
 - ✓ Normal
 - ✓ Ancho: Bloqueo de rama, WPW, Extrasistolia Ventricular, Marcapasos
- ✓ QTc
- ✓ Calculo del eje del QRS en el plano frontal
 - ✓ Normal
 - ✓ Izquierdo: Hemibloqueo anterior
 - ✓ Derecho: Crecimiento VD, Hemibloqueo posterior
- ✓ Análisis de las ondas
 - ✓ Onda P
 - ✓ Amplitud
 - ✓ Duración
 - ✓ Morfología
 - ✓ Complejo QRS
 - ✓ Amplitud
 - ✓ Duración
 - ✓ Morfología
 - ✓ Segmento ST
 - ✓ Morfología
 - ✓ Onda T
 - ✓ Morfología

Interpretación del E.C.G.

Evaluación de la onda P

✓ Voltaje de la onda P en II:

✓ Normal

✓ Aumentado

Crecimiento de AD

✓ Duración de la onda P en II:

✓ Normal

✓ Aumentada

Crecimiento de AI

✓ Morfología en V_1 :

✓ Normal

✓ Aumento módulo negativo

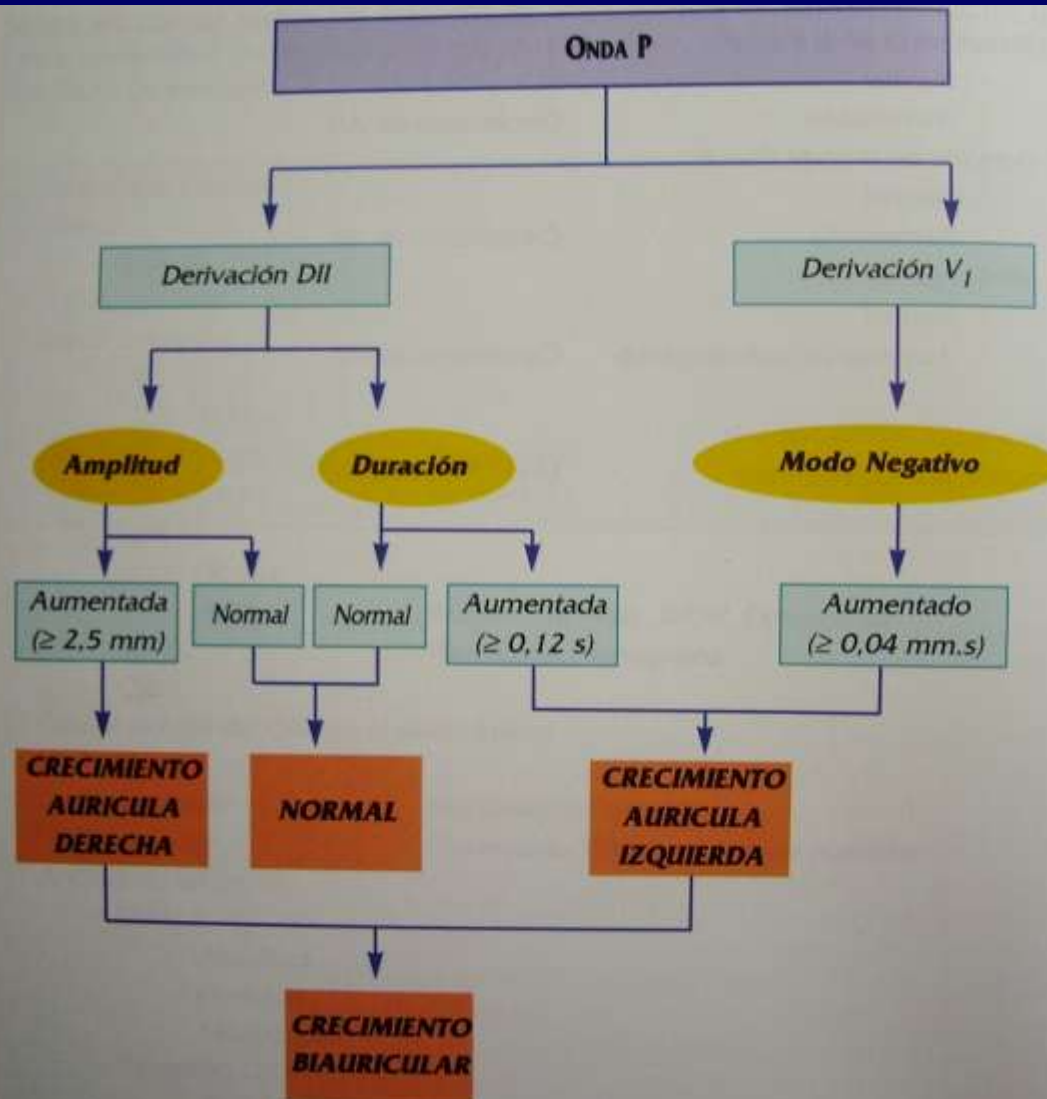
Crecimiento de AI

Si el voltaje, la duración y la morfología son normales:

Onda P normal

Interpretación del E.C.G.

Evaluación de la onda P



Interpretación del E.C.G.

Evaluación del complejo QRS

✓ Duración del complejo QRS:

✓ Complejo QRS de duración aumentada (ensanchado):

✓ Medir intervalo PR:

✓ Corto:

Preexcitación

✓ Normal:

Trastorno de conducción

✓ Morfología en V_1 :

✓ rSR' :

Bloqueo de rama derecha

✓ QS o rS:

Bloqueo de rama izquierda

Una vez establecido el diagnóstico de preexcitación o de bloqueo de rama (especialmente izquierda) hay que ser muy cauto en la interpretación del ECG, puesto que no pueden utilizarse los criterios habituales de crecimiento de cavidades o necrosis, por ejemplo:

✓ Complejo QRS de duración normal:

✓ Calcular el eje del QRS:

✓ Si el eje es izquierdo:

Hemibloqueo anterior

✓ Si el eje es derecho:

Hemibloqueo posterior (raro)

✓ Si es normal:

✓ Voltaje aumentado:

Crecimiento ventricular

✓ Morfología específica CVI o CVD

✓ Ondas de necrosis:

Infarto de miocardio

✓ Localización de la necrosis:

✓ Anterior

✓ Inferior (posterior)

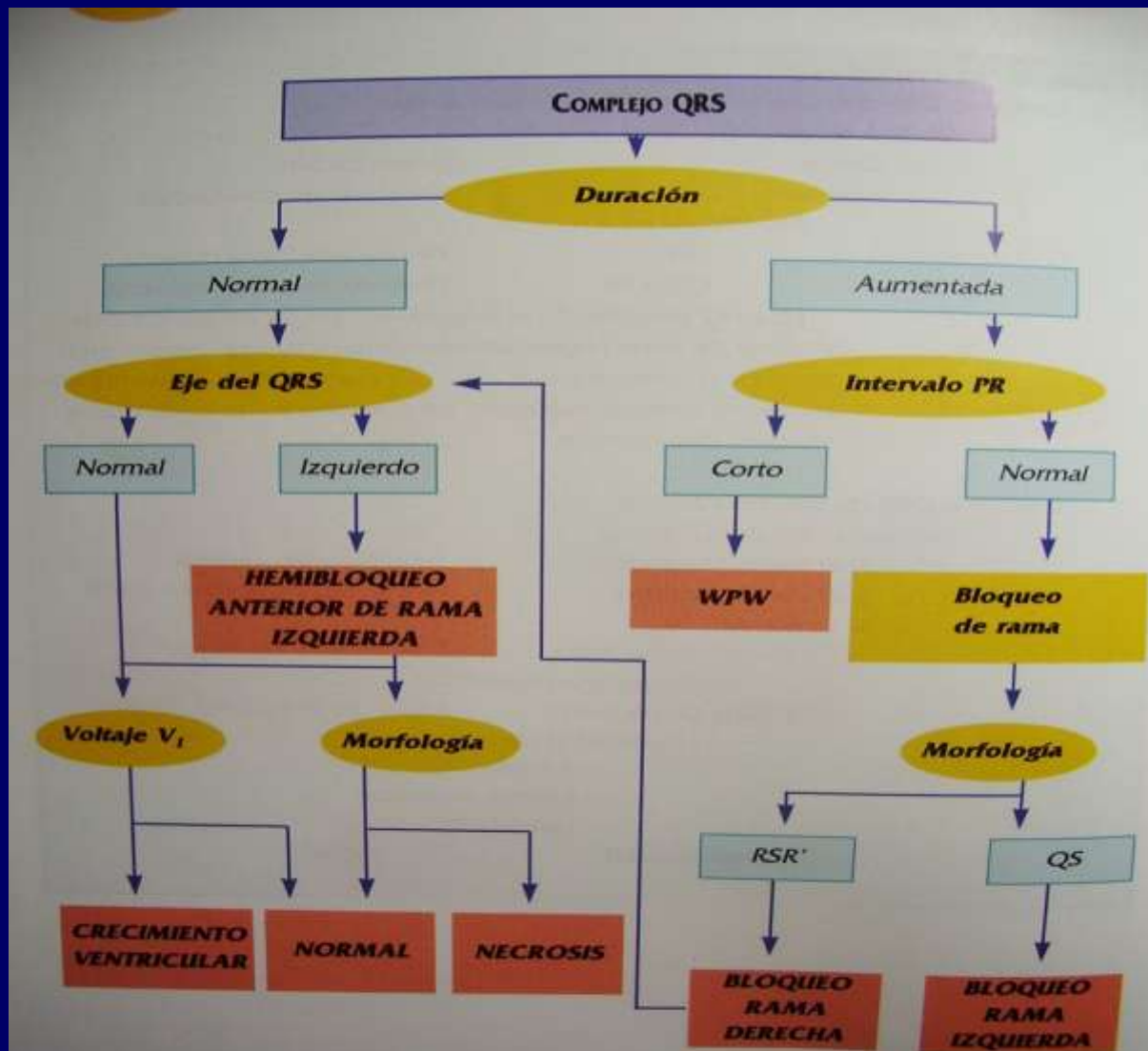
✓ Lateral alto

✓ Voltaje normal:

QRS normal

Interpretación del E.C.G.

Evaluación del complejo QRS



Interpretación del E.C.G.

Evaluación del segmento ST

✓ ST elevado:

✓ Primario:

- ✓ Lesión subepicárdica: Infarto agudo de miocardio, vasoespasmo coronario

✓ Otros:

- ✓ Pericarditis
- ✓ Aneurisma
- ✓ Tumor
- ✓ Cor pulmonale agudo
- ✓ Repolarización precoz

✓ ST descendido:

✓ Primario:

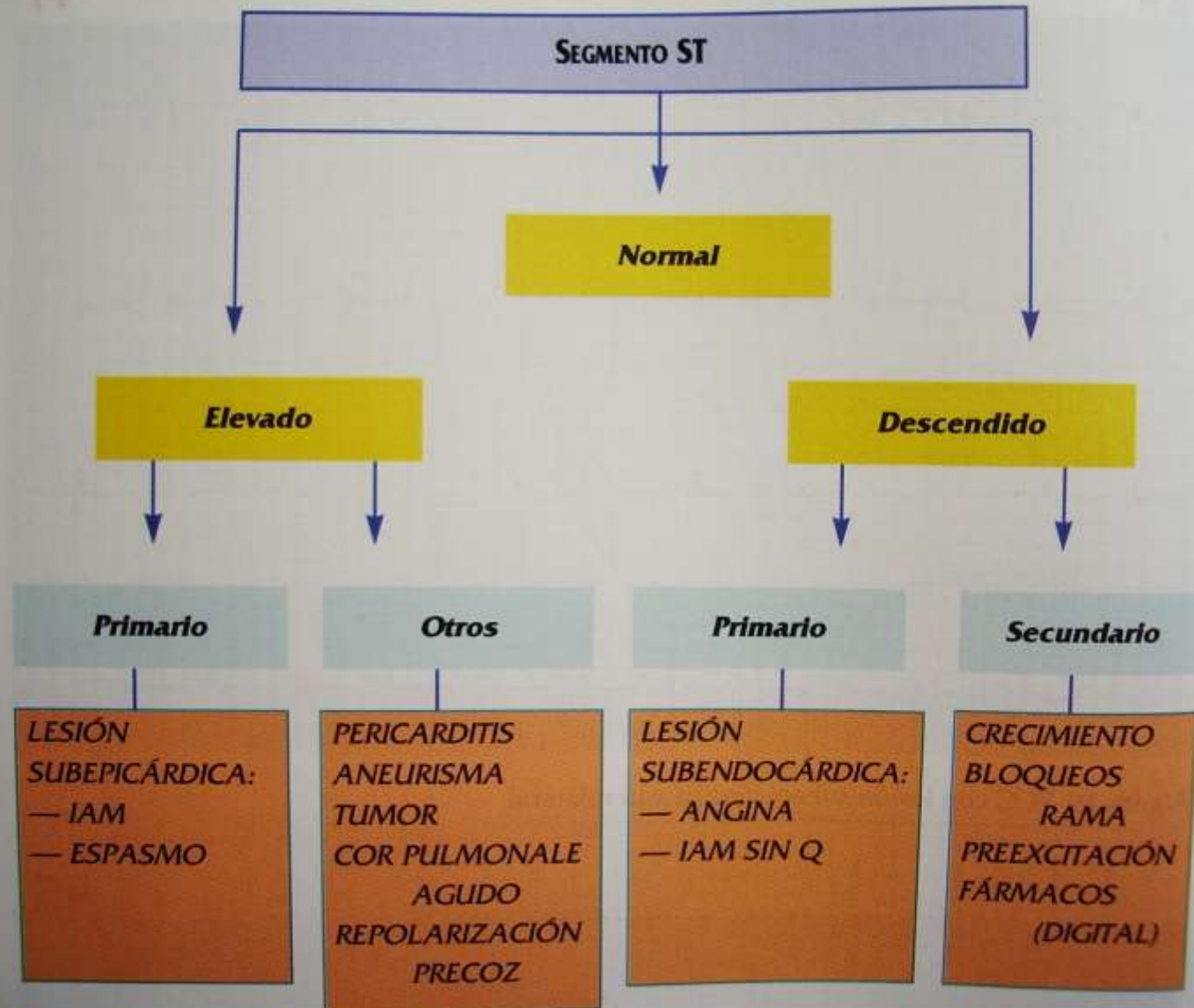
- ✓ Lesión subendocárdica: Angina inestable, infarto no-Q

✓ Secundario:

- ✓ Crecimiento de ventrículos
- ✓ Trastorno de conducción
- ✓ Preexcitación
- ✓ Fármacos (dígital)

Interpretación del E.C.G.

Evaluación del segmento ST



Interpretación del E.C.G.

Evaluación de la onda T

✓✓ Onda T aumentada:

✓✓ Primaria:

✓✓ *Isquemia subendocárdica: Fase inicial del infarto de miocardio*

✓✓ Secundaria:

✓✓ *Efecto vagal*

✓✓ *Sobrecarga de volumen del VI*

✓✓ *Hiperpotasemia*

✓✓ Onda T invertida:

✓✓ Primaria:

✓✓ *Isquemia subepicárdica: Angina inestable*

✓✓ Secundaria:

✓✓ *Crecimiento de ventrículos*

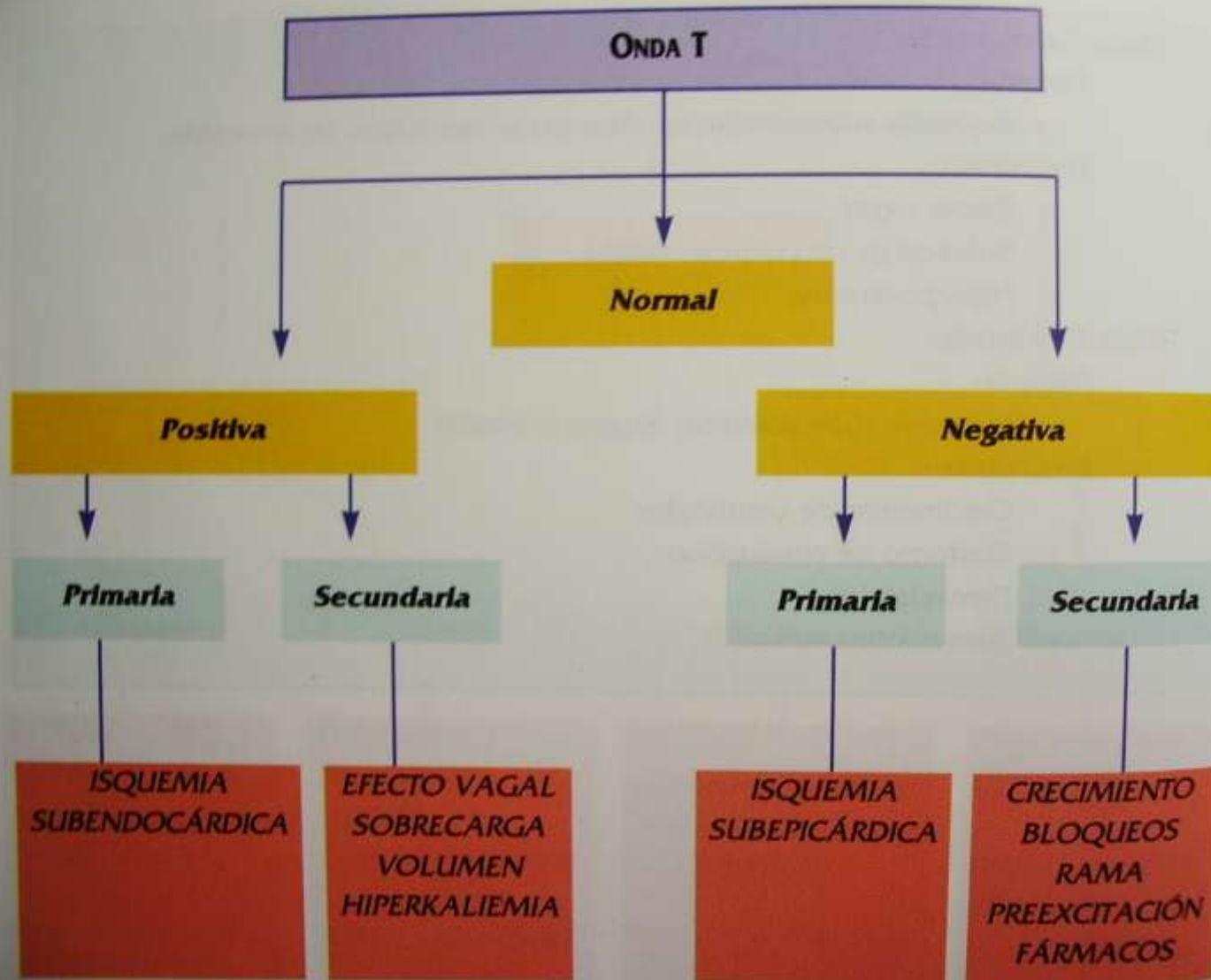
✓✓ *Trastorno de conducción*

✓✓ *Preexcitación*

✓✓ *Alteraciones iónicas*

Interpretación del E.C.G.

Evaluación de la onda T



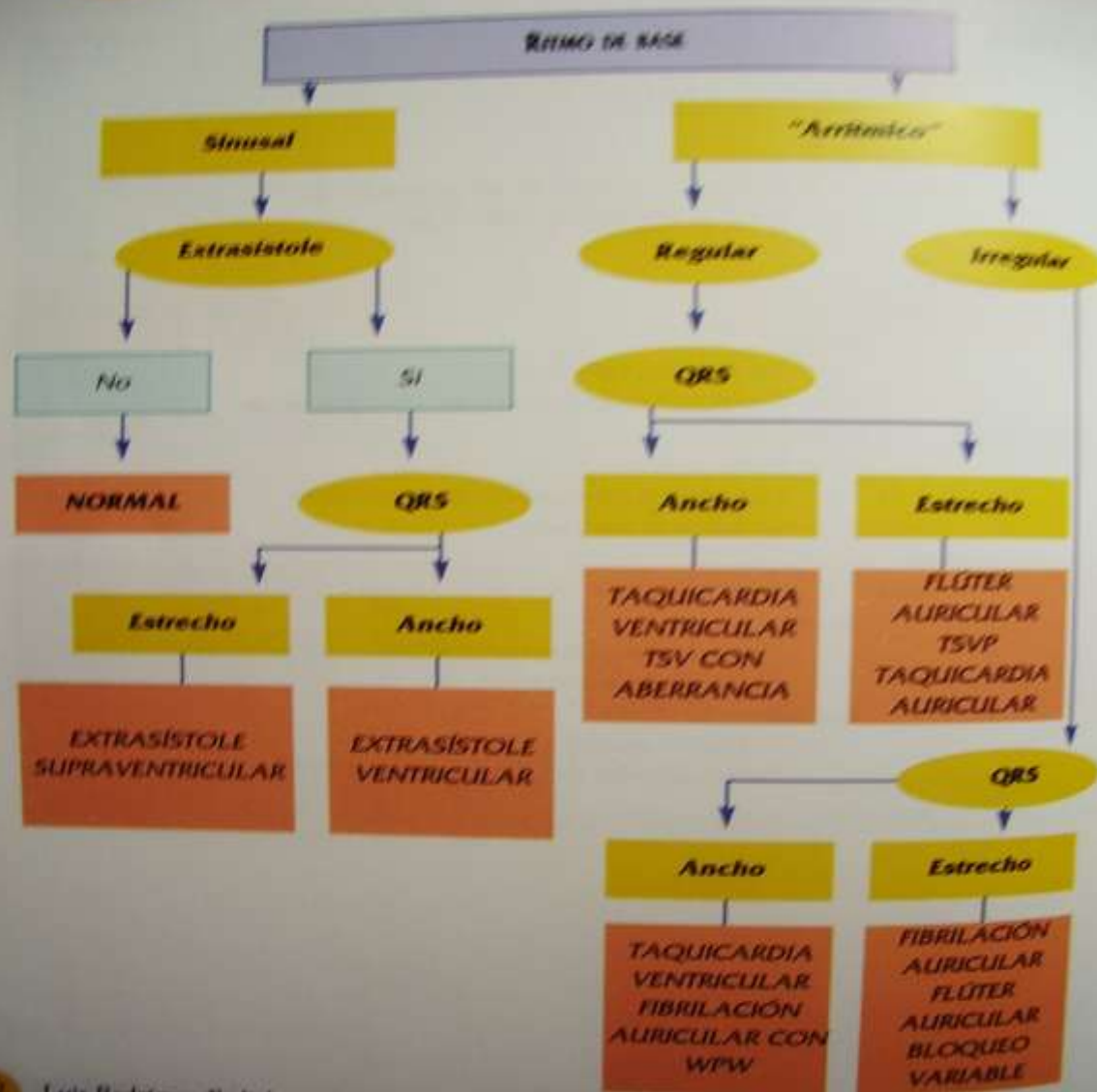
Interpretación del E.C.G.

El Ritmo cardiaco

- ✓ Sinusal:
 - ✓ Extrasístole:
 - ✓ No: Ritmo Sinusal Normal
 - ✓ Si
 - ✓ QRS:
 - ✓ Estrecho: Extrasístole supraventricular
 - ✓ Ancho: Extrasístole ventricular
- ✓ "Arrítmico"
 - ✓ Regular:
 - ✓ QRS:
 - ✓ Ancho:
 - ✓ Taquicardia ventricular
 - ✓ Taquicardia supraventricular con aberrancia
 - ✓ Estrecho:
 - ✓ Flúter auricular
 - ✓ Taquicardia supraventricular paroxística
 - ✓ Taquicardia auricular
 - ✓ Irregular:
 - ✓ QRS:
 - ✓ Ancho:
 - ✓ Fibrilación auricular con aberrancia o preexcitación (WPW)
 - ✓ Taquicardia ventricular
 - ✓ Estrecho:
 - ✓ Fibrilación auricular
 - ✓ Flúter auricular con bloqueo AV variable

Interpretación del E.C.G.

El Ritmo cardiaco



Evaluación de Taquicardia QRS estrecho

✓ Irregular:

- ✓ Fibrilación auricular:
- ✓ Flúter auricular con bloqueo AV variable
- ✓ Taquicardia auricular multifocal

✓ Regular:

✓ Onda P visible:

✓ Bloqueo AV:

- ✓ Taquicardia auricular
- ✓ Taquicardia no paroxística de la unión (con disociación auriculo-ventricular)
- ✓ Taquicardia supraventricular paroxística por reentrada en el nodo AV (con bloqueo infrahisiano)

✓ No bloqueo AV:

✓ $RP < PR$:

- ✓ Taquicardia supraventricular paroxística por reentrada en el nodo AV
- ✓ Taquicardia por reentrada auriculoventricular (taquicardia ortodrómica del WPW)
- ✓ Taquicardia auricular

✓ $RP > PR$:

✓ P negativa en II, III y aVF:

- ✓ Taquicardia reciprocante de la unión (forma incesante)
- ✓ Taquicardia supraventricular paroxística por reentrada en el nodo AV
- ✓ Taquicardia auricular

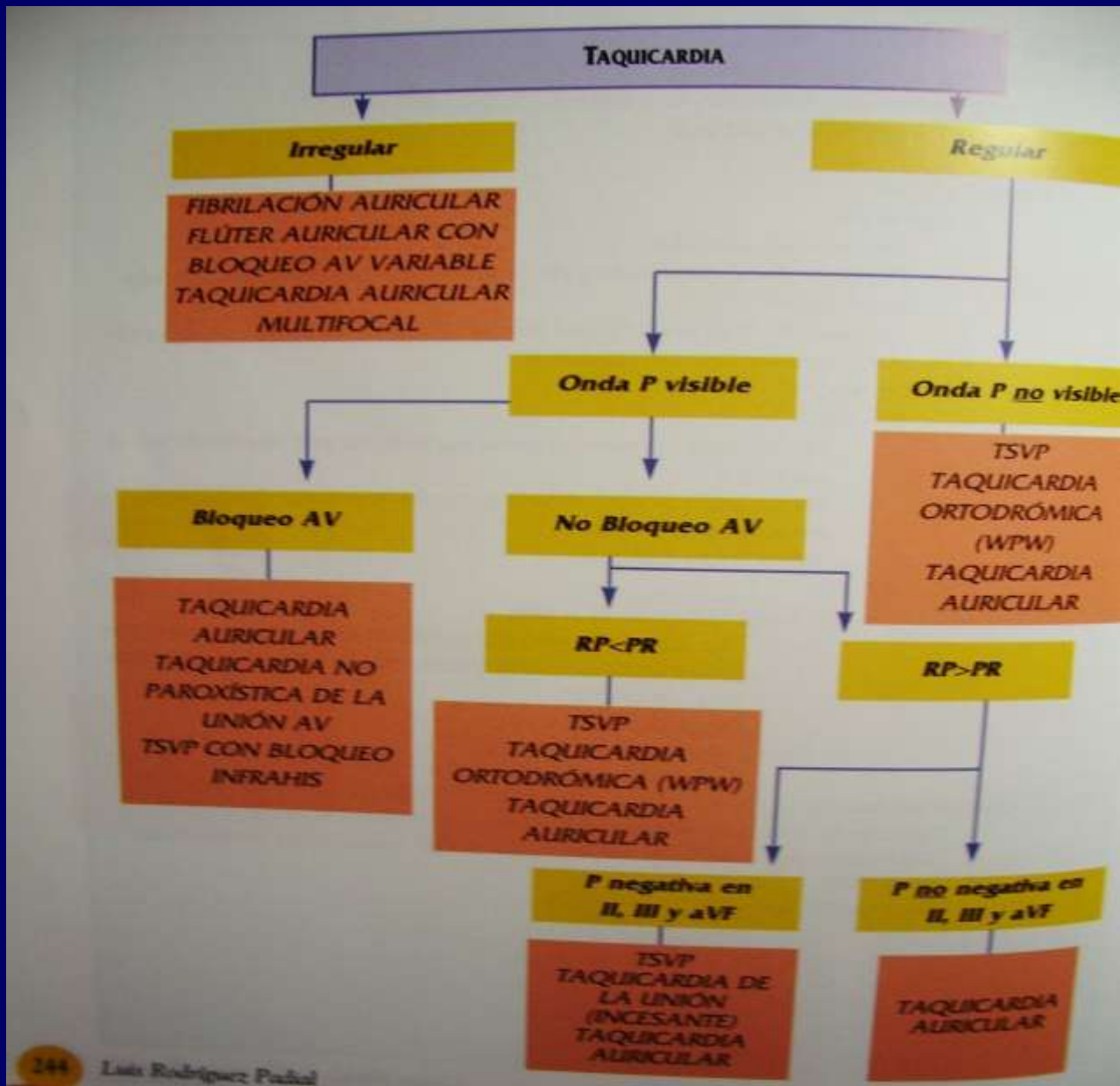
✓ P no negativa en II, III y aVF:

- ✓ Taquicardia auricular

✓ Onda P no visible:

- ✓ Taquicardia supraventricular paroxística por reentrada en el nodo AV
- ✓ Taquicardia por reentrada auriculoventricular (taquicardia ortodrómica del WPW)
- ✓ Taquicardia auricular

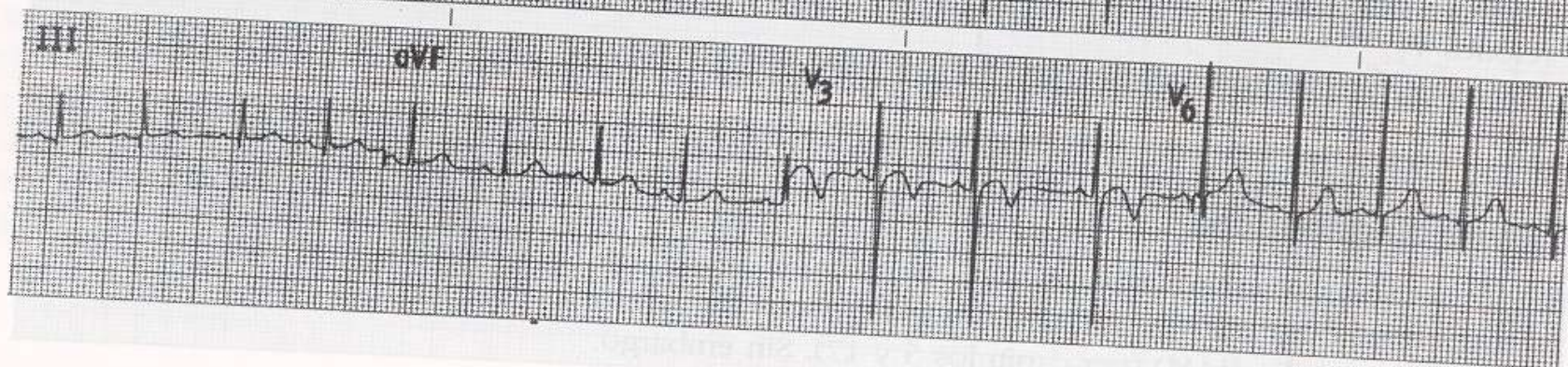
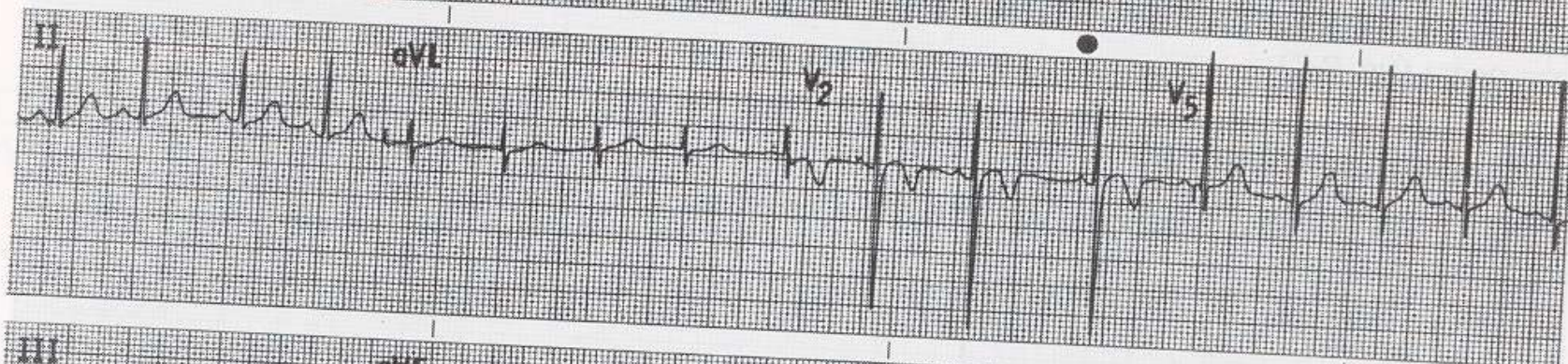
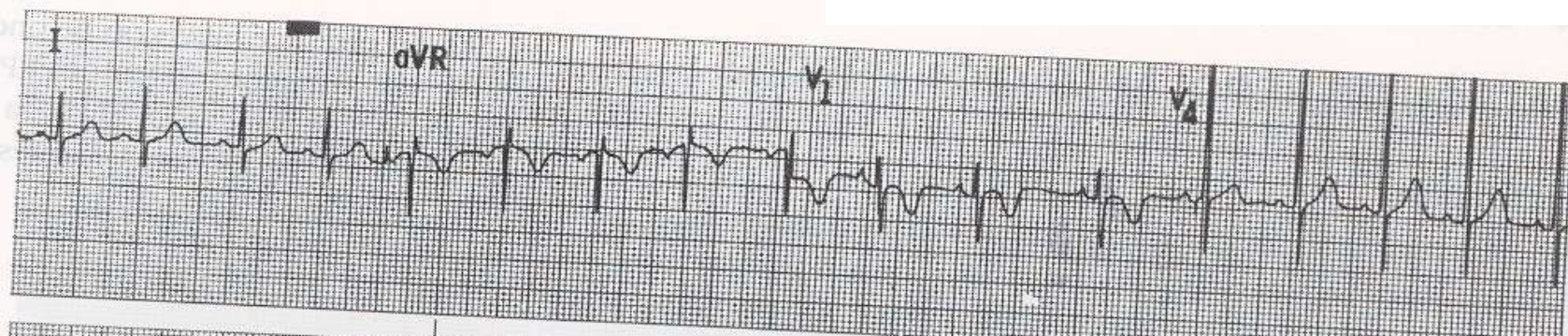
Evaluación de Taquicardia QRS estrecho

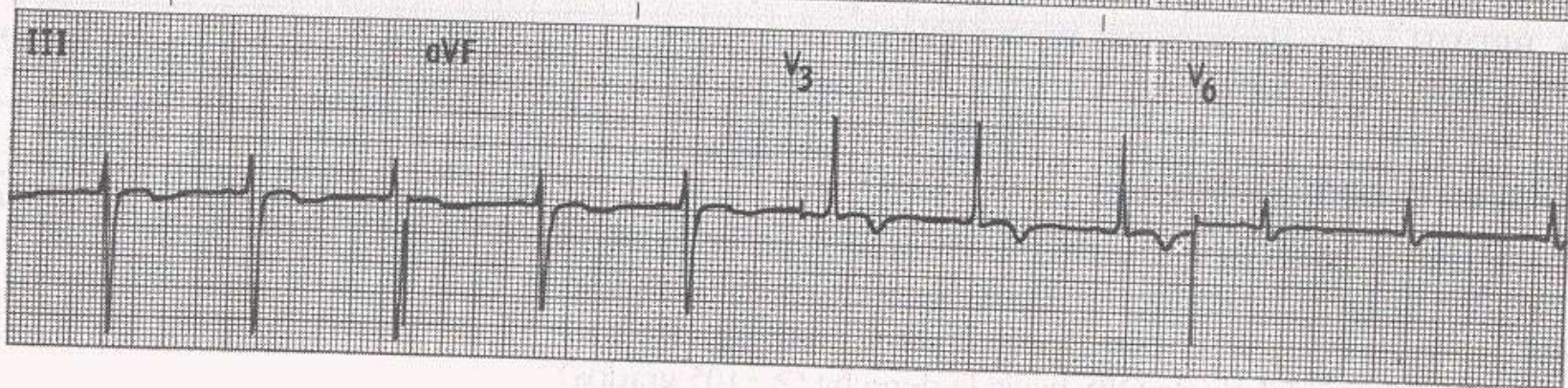
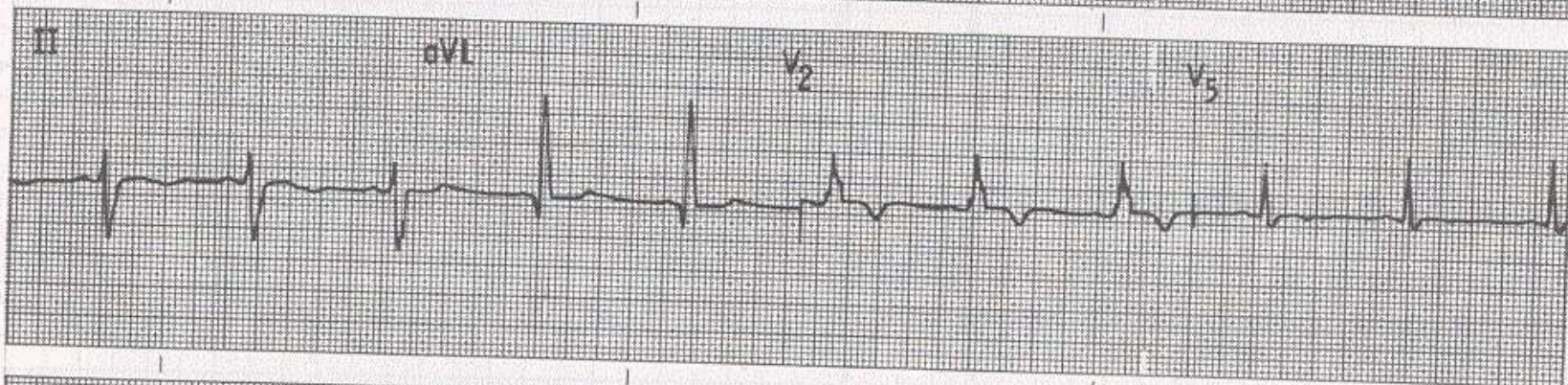
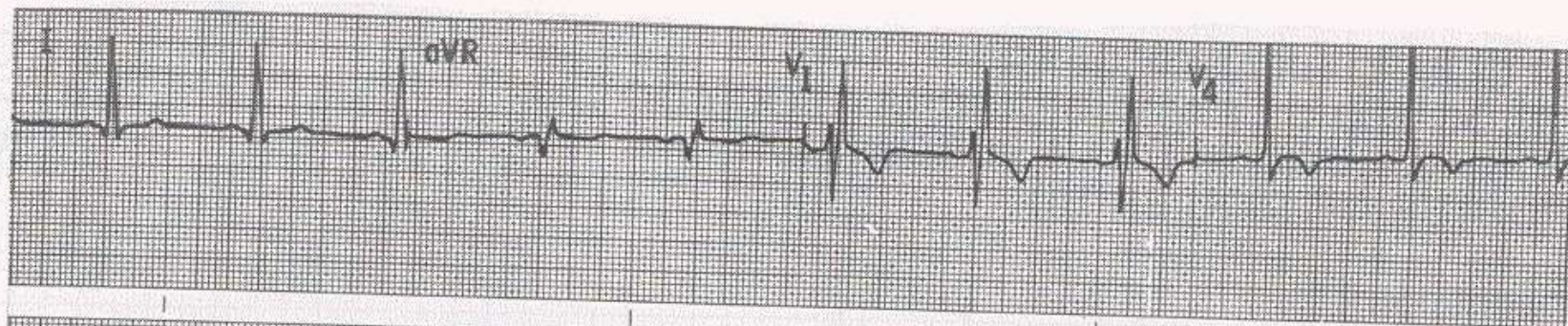


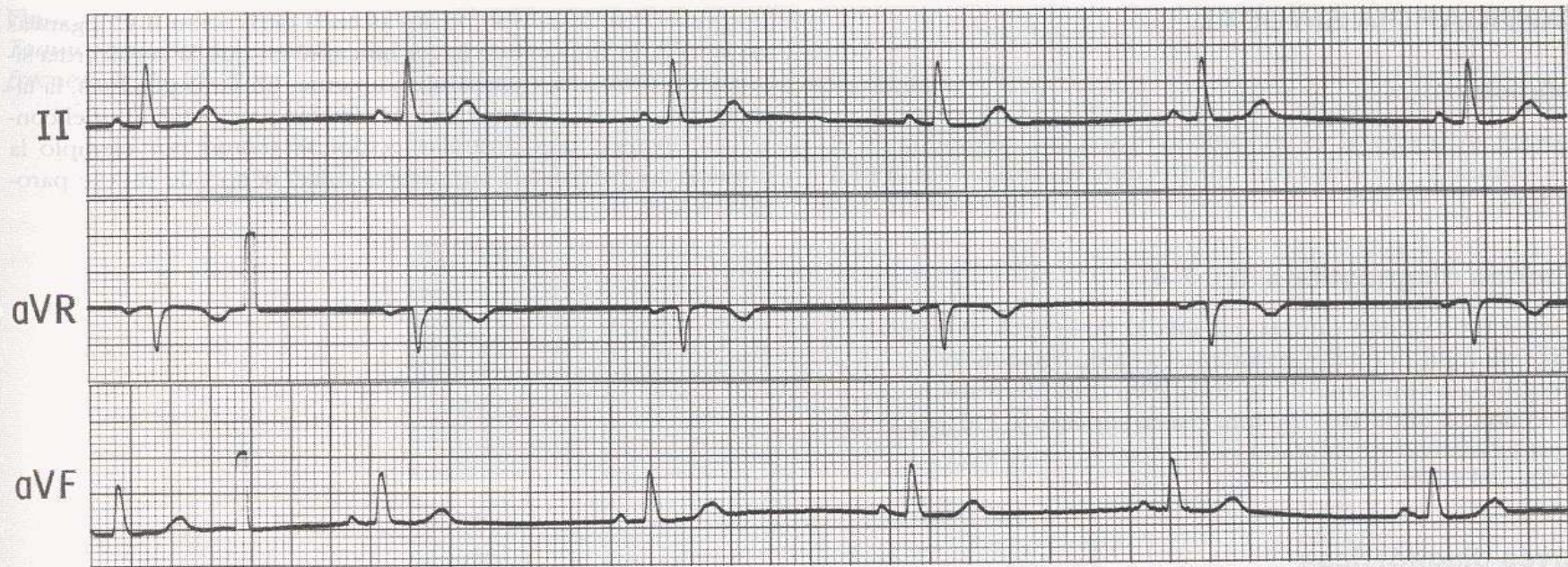
CURSO DE ELECTROCARDIOGRAFÍA BÁSICA

Algunos ECG prácticos

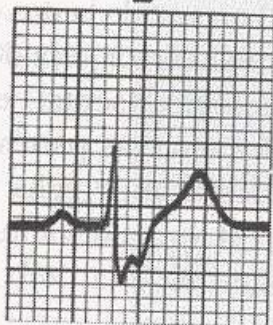
Dr. F. Richard



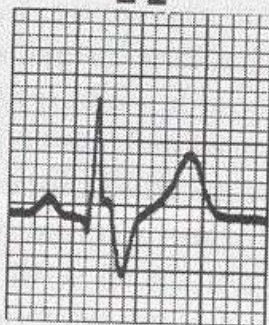




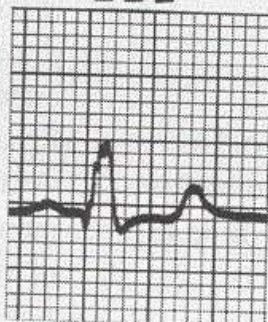
I



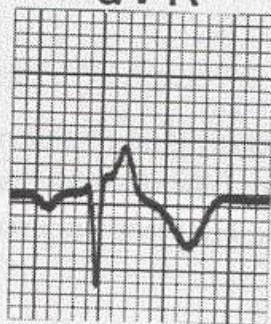
II



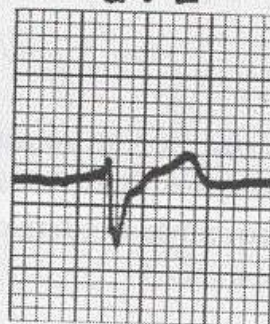III



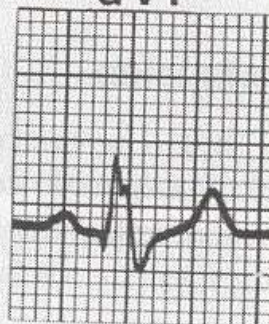
aVR



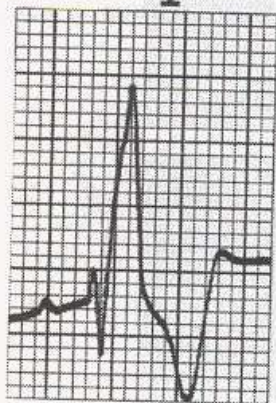
aVL



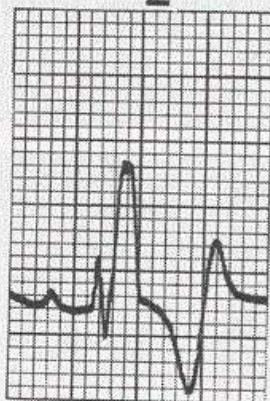
aVF



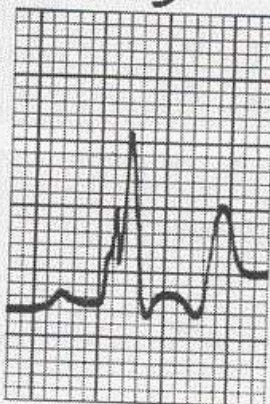
V₁



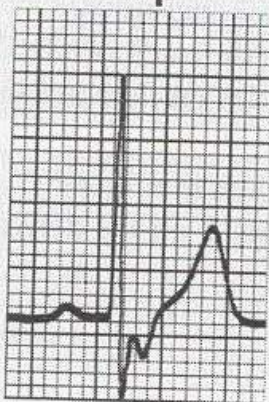
V₂



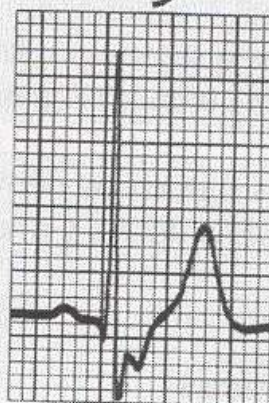
V₃



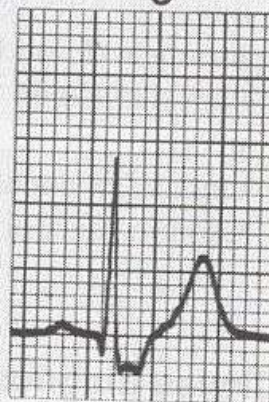
V₄

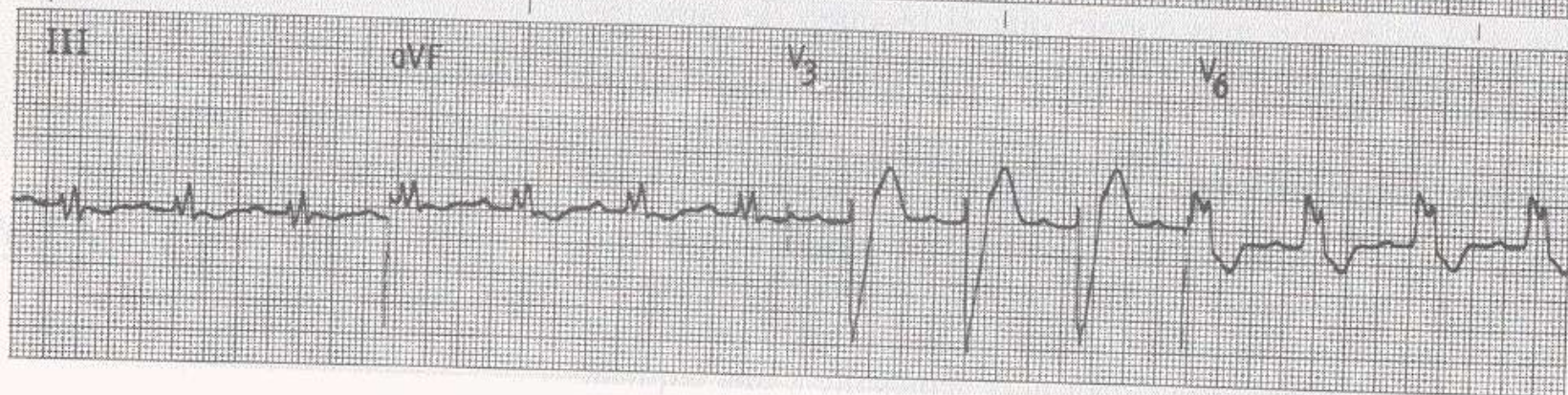
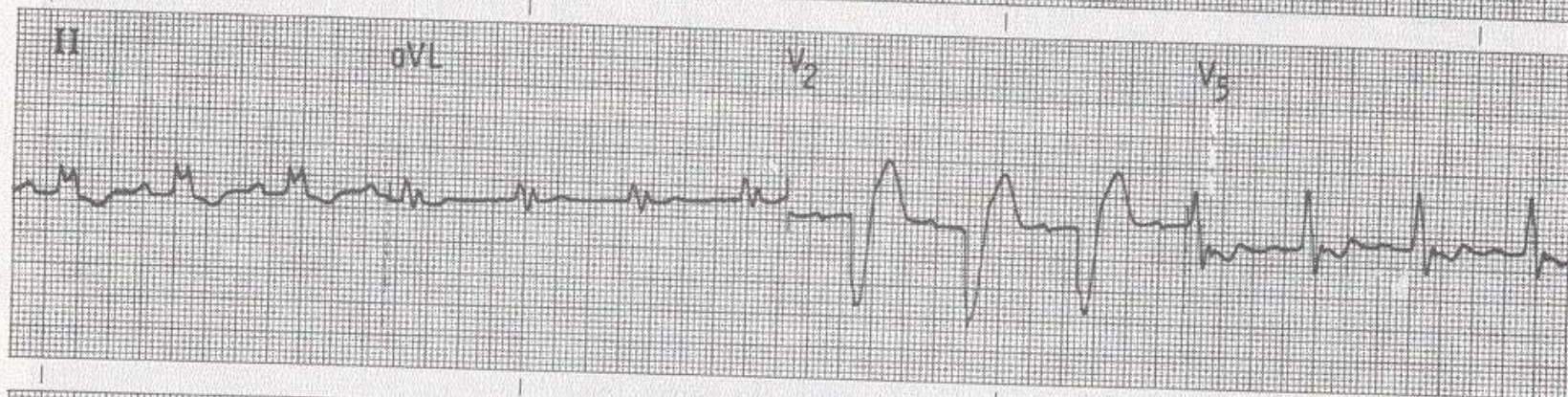
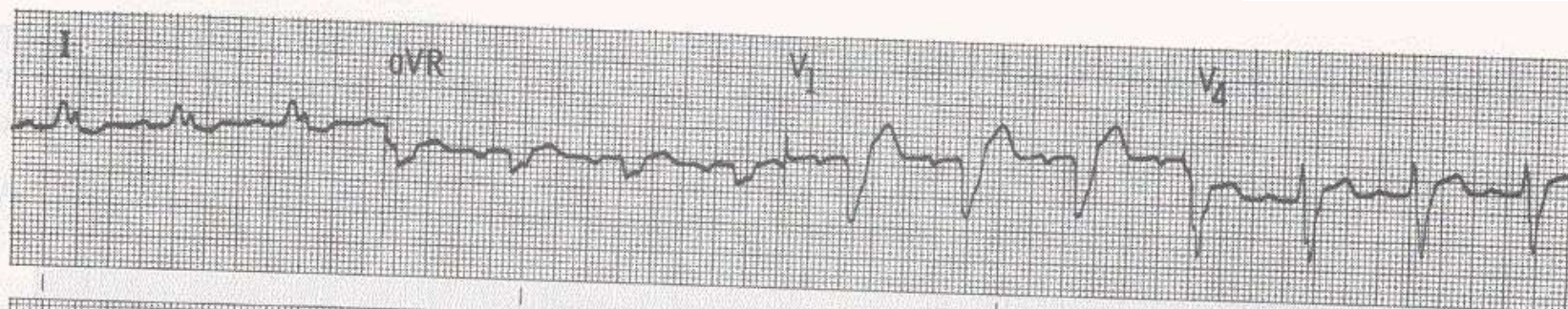


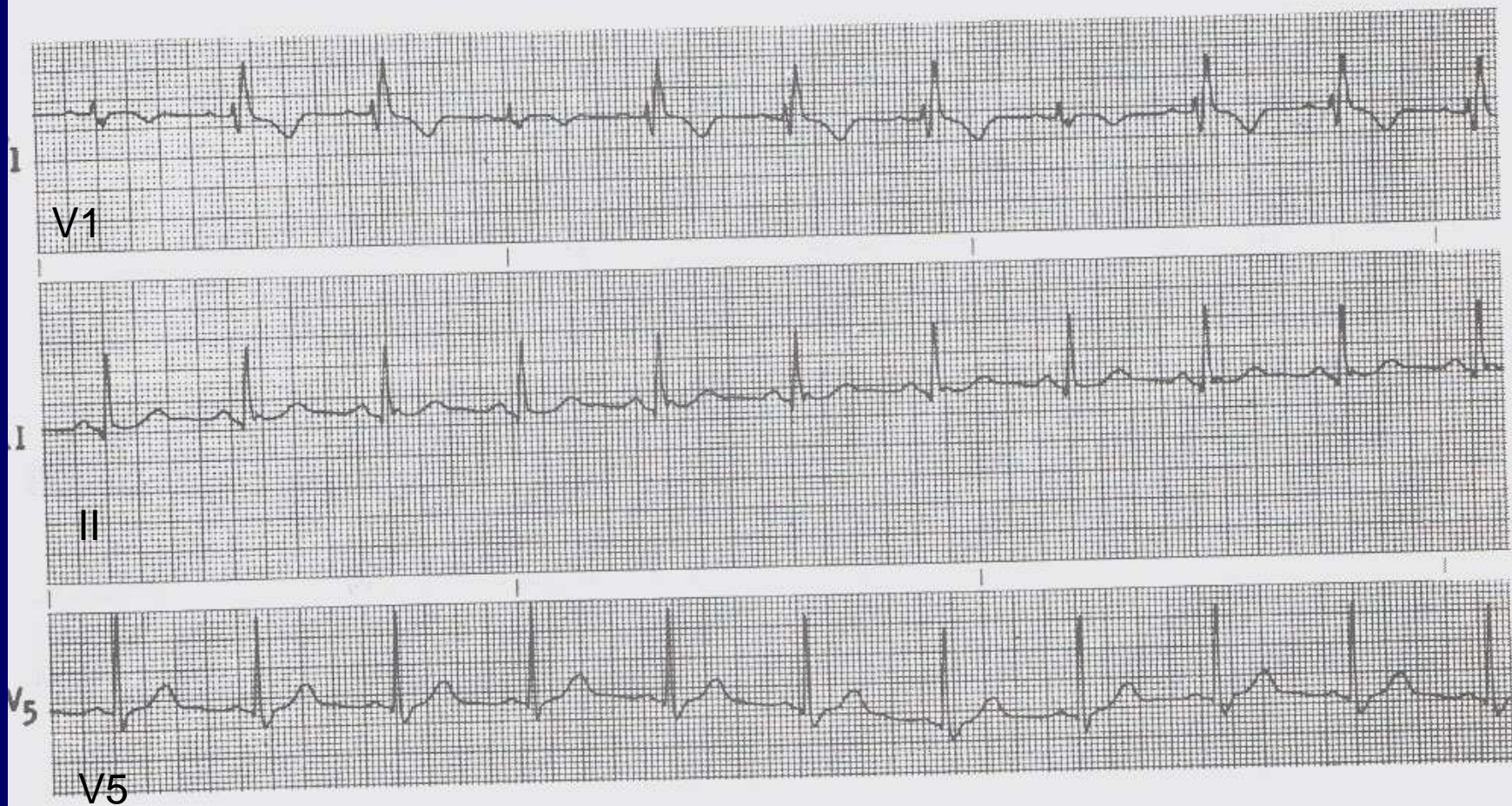
V₅



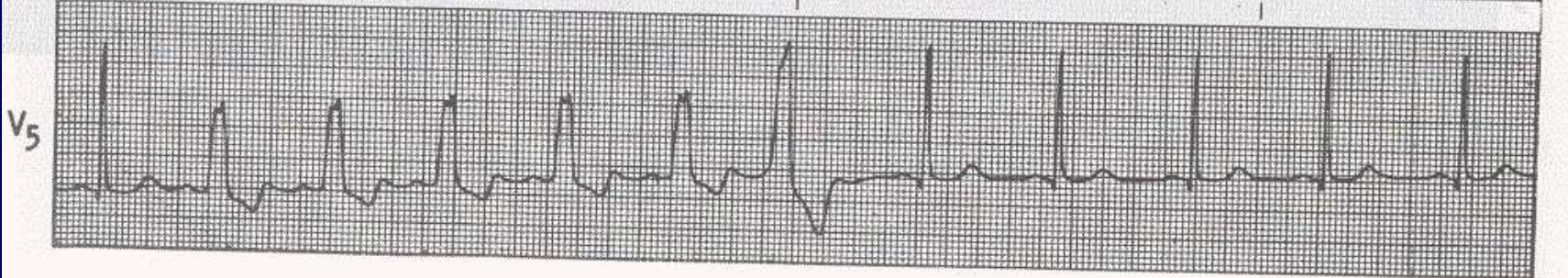
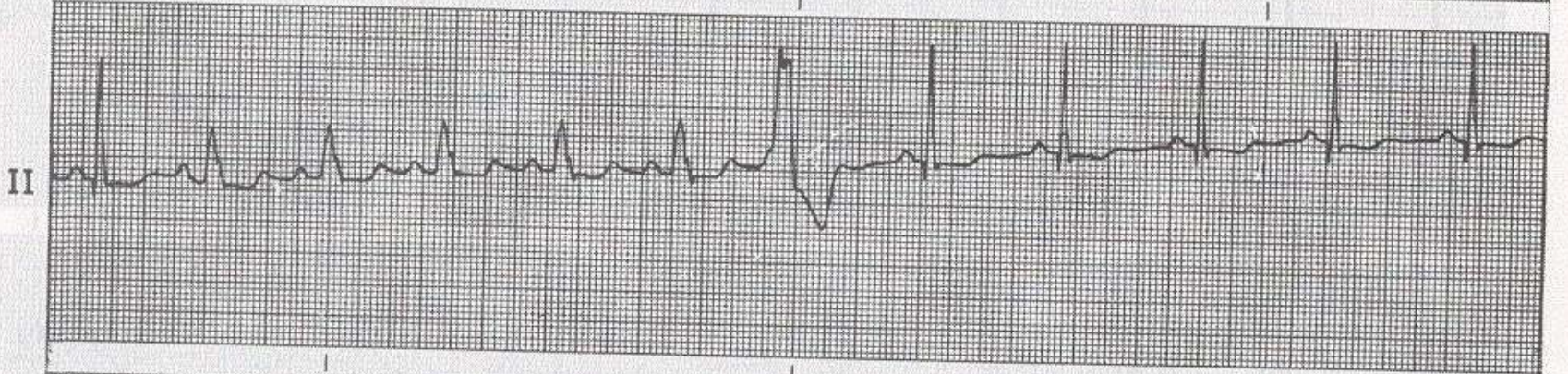
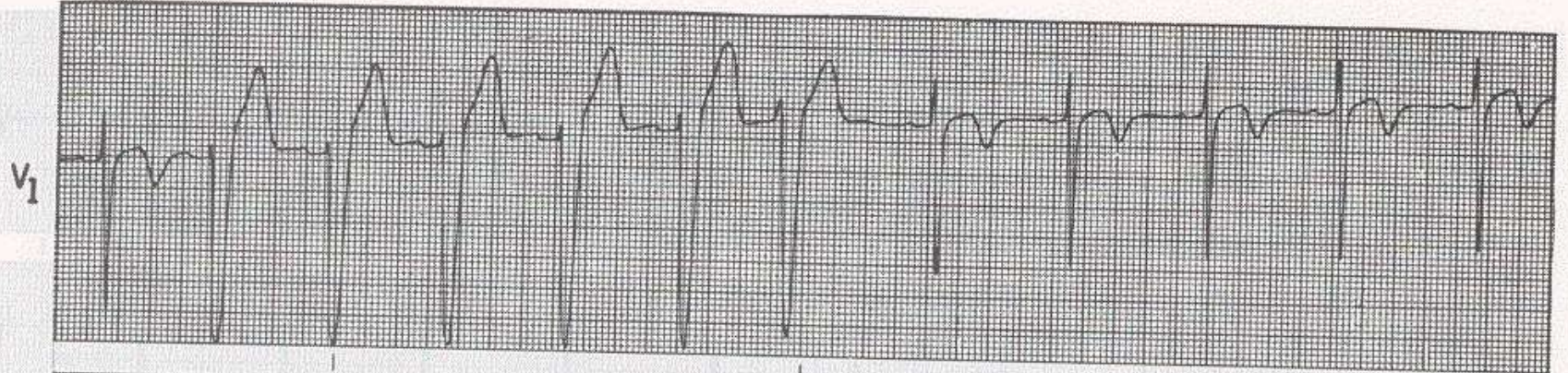
V₆







B

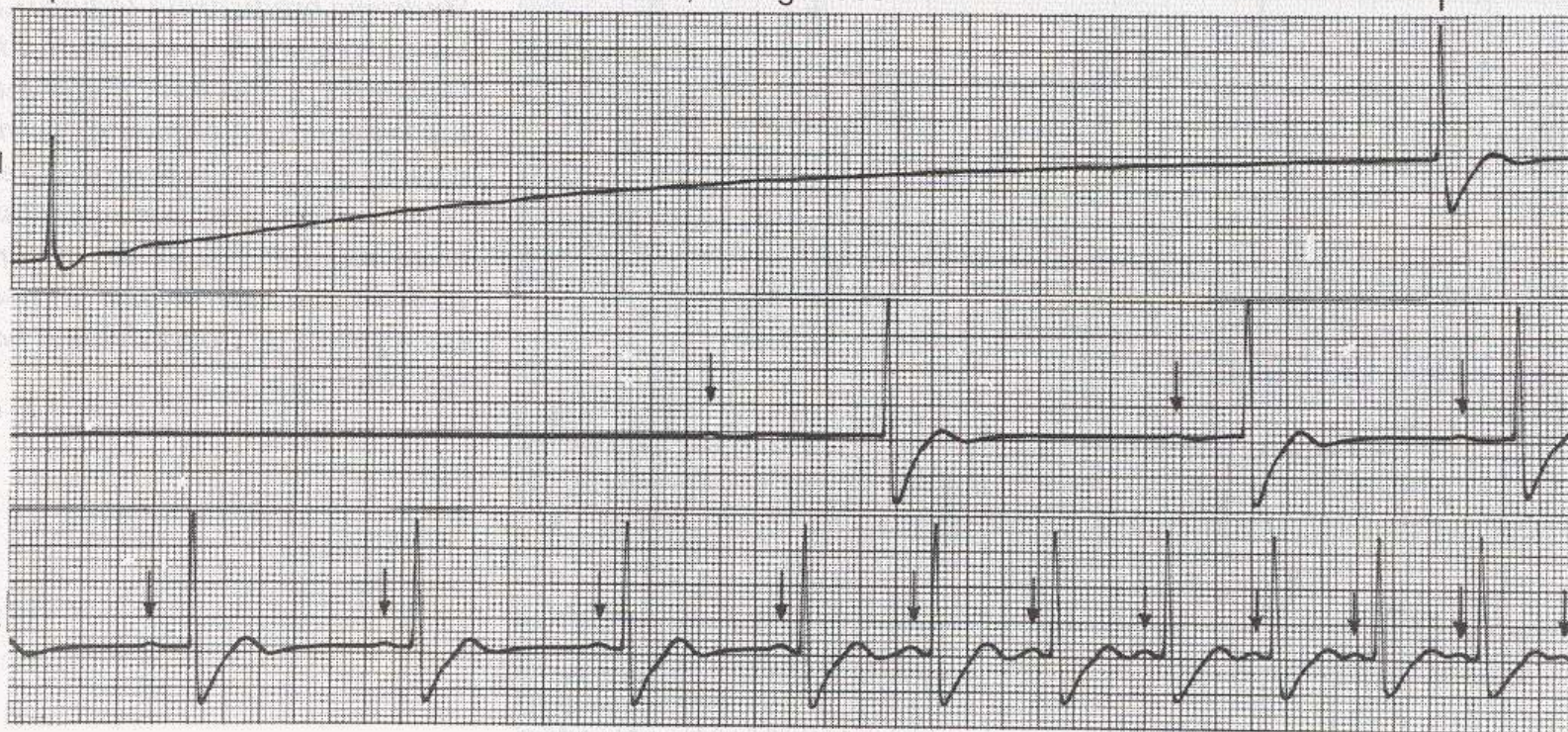


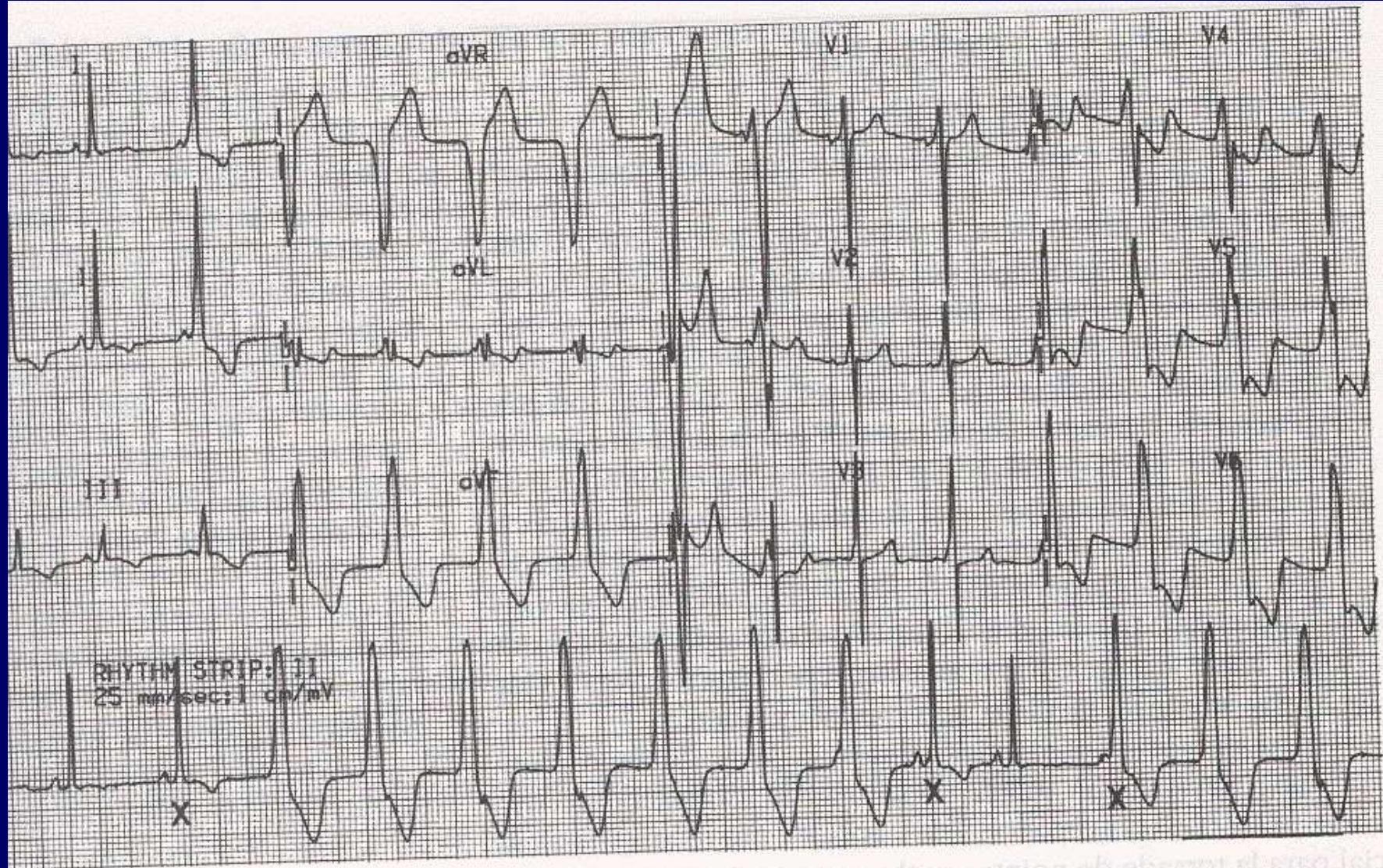
7,86 segundos

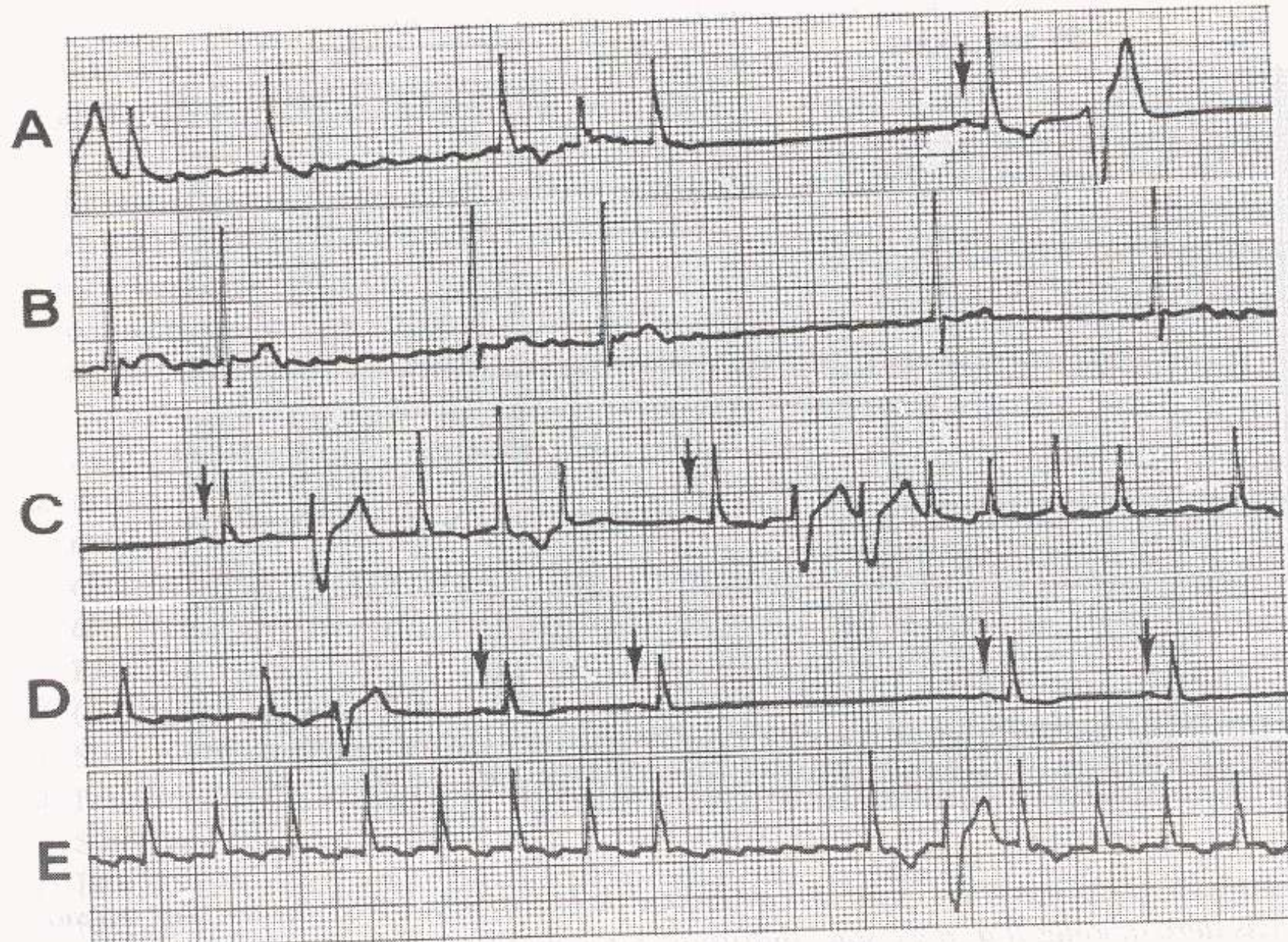
II-a

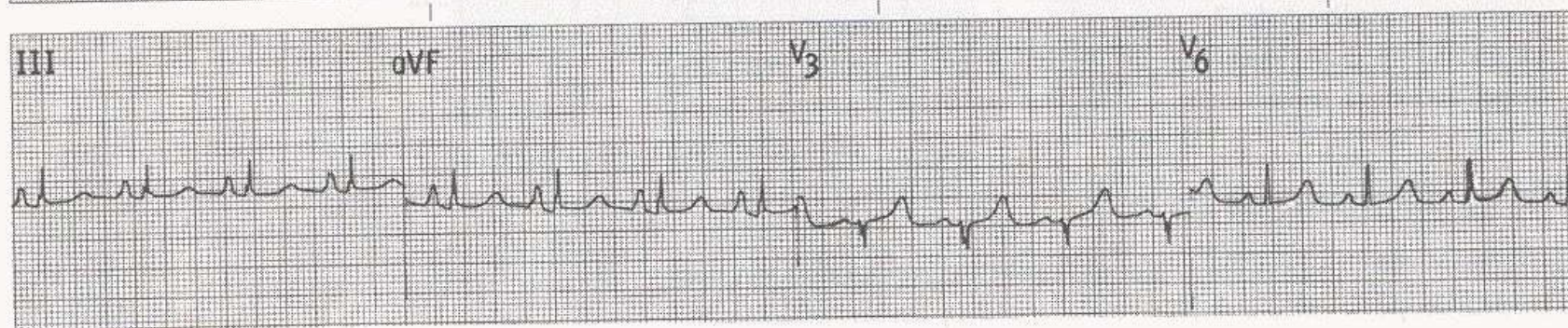
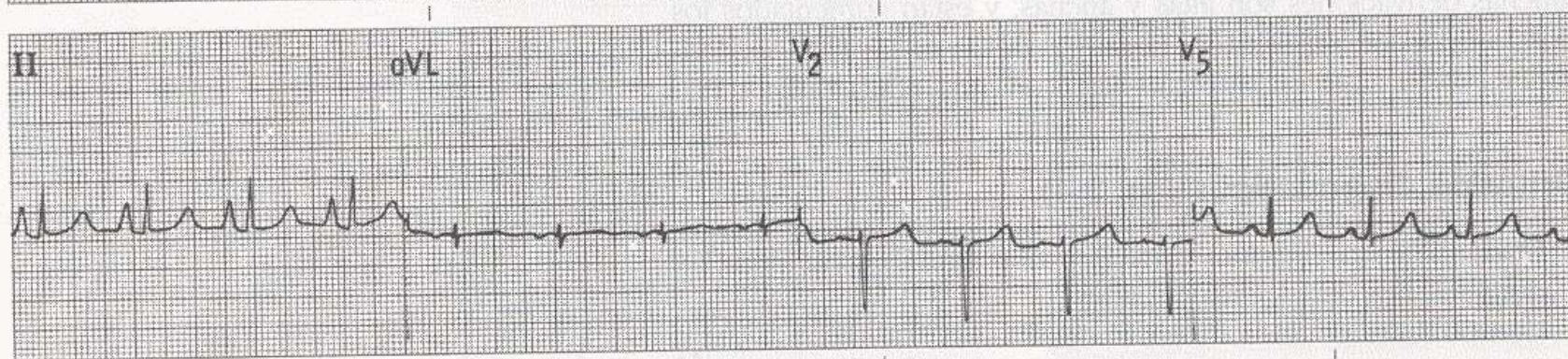
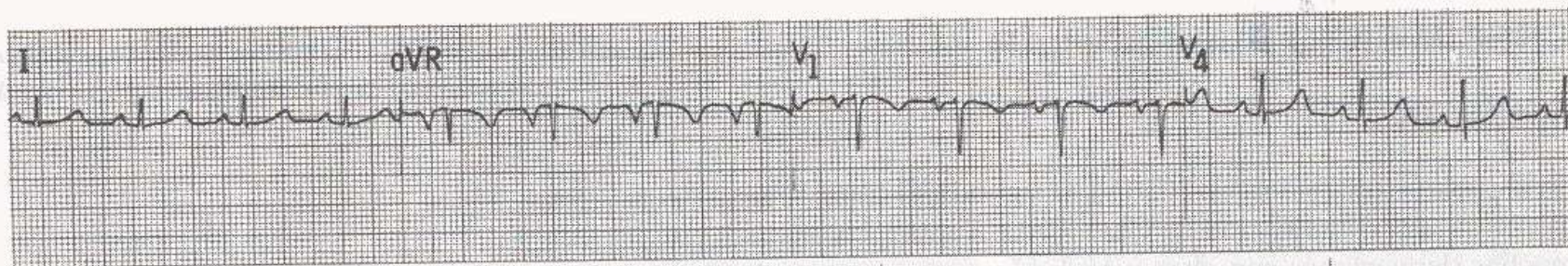
II-b

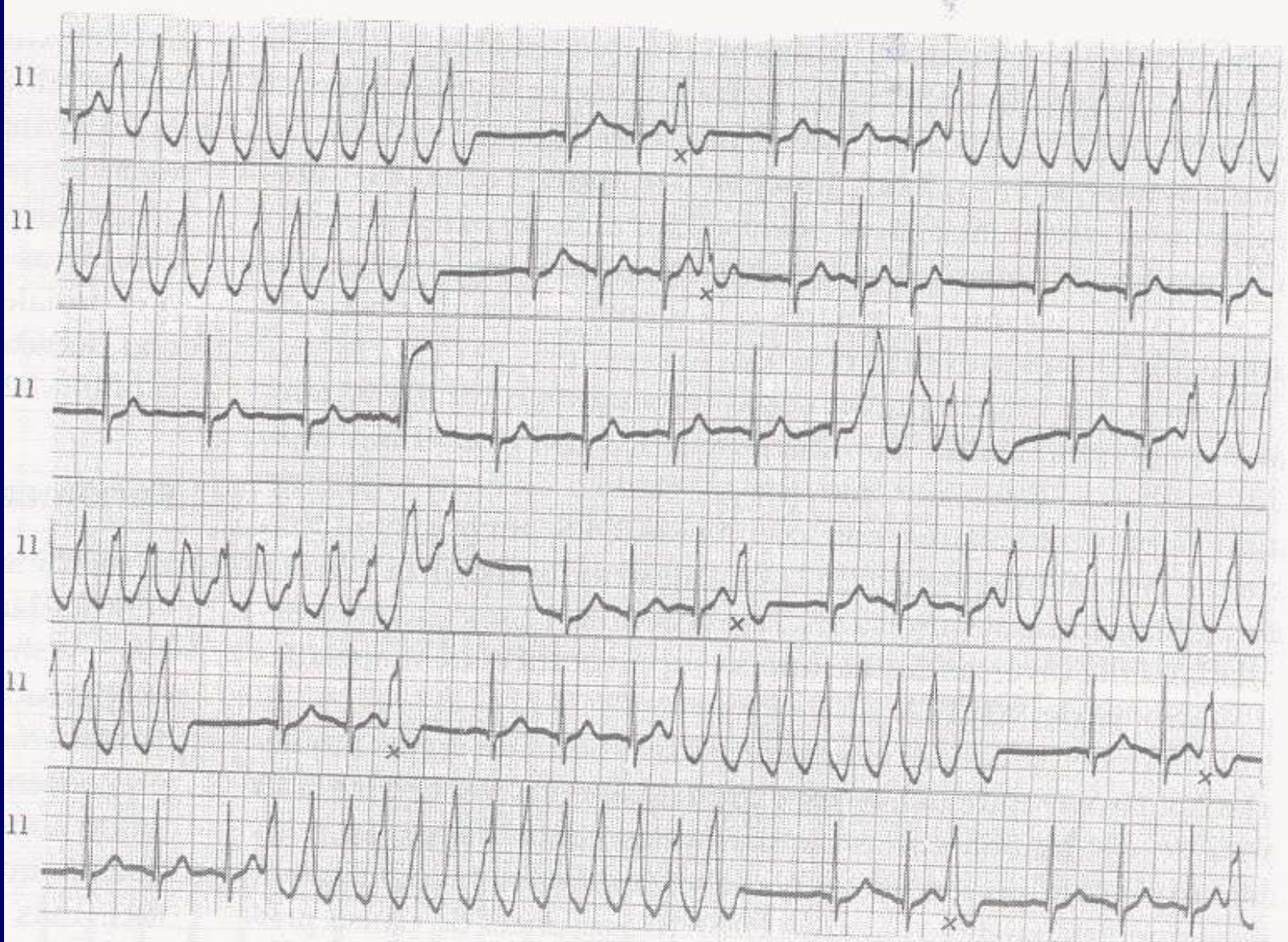
II-c

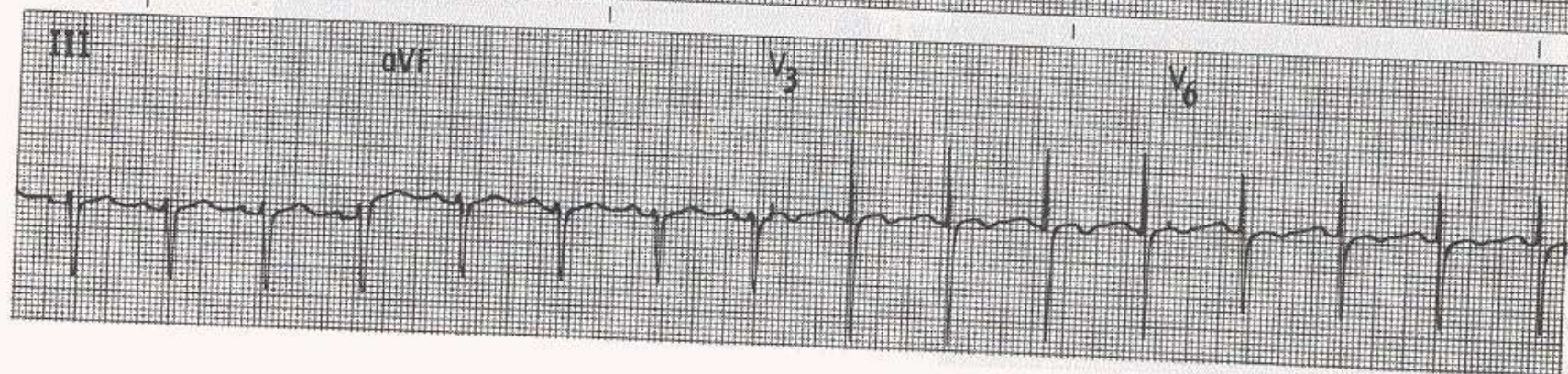
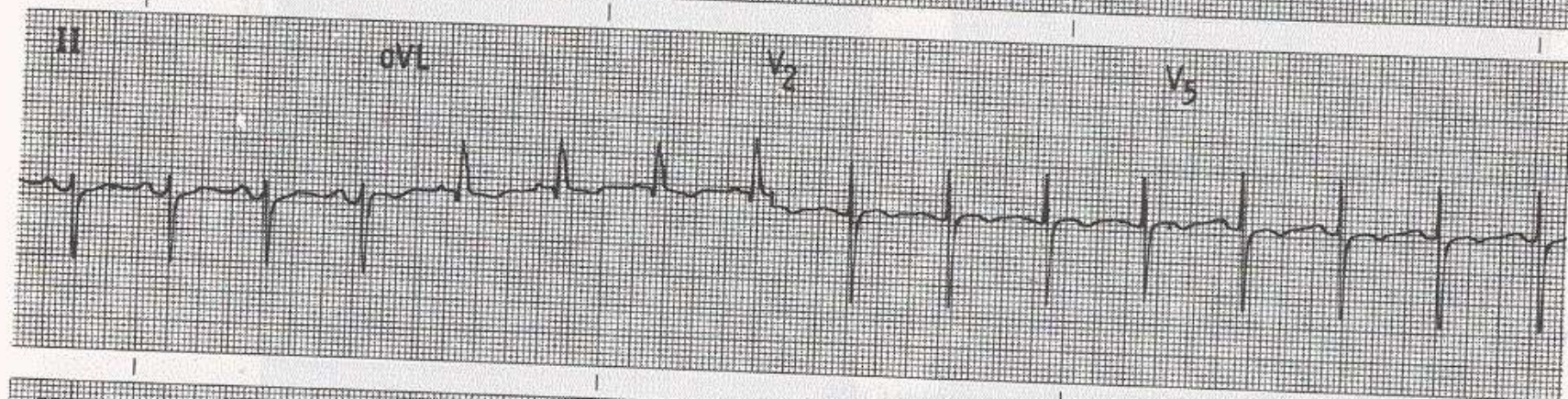
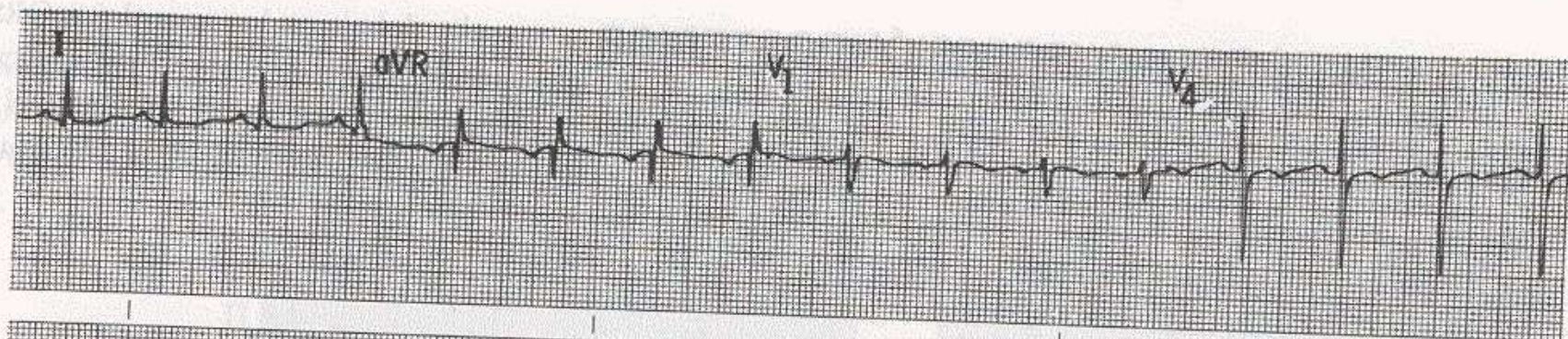


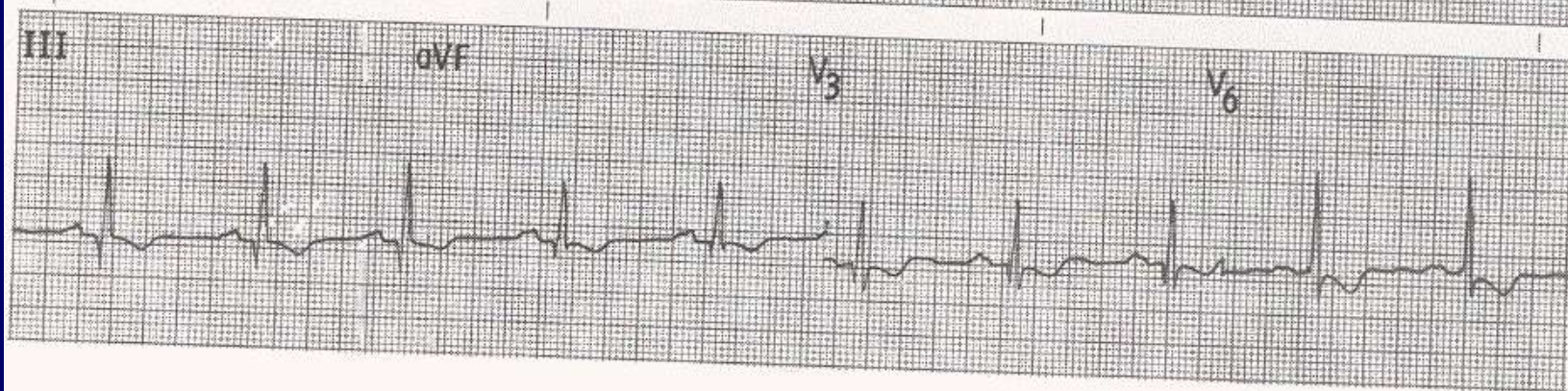
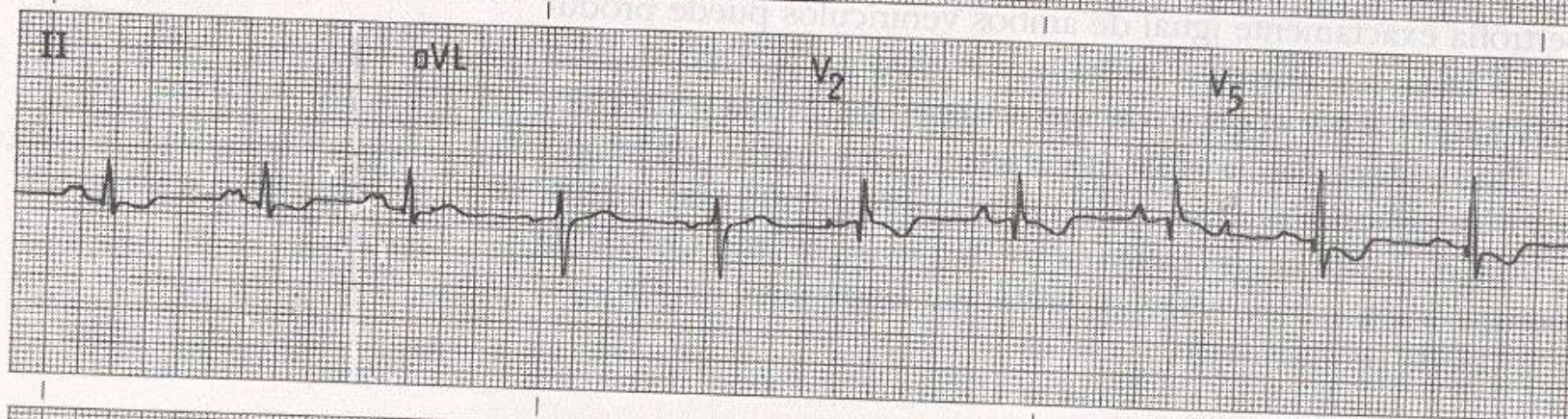
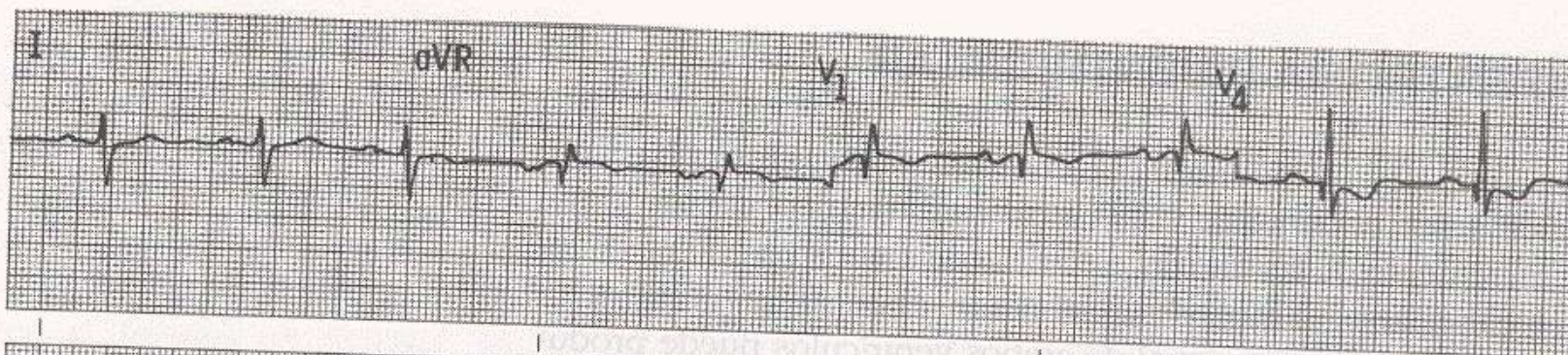












I

II

III

VR

VL

VF

VI

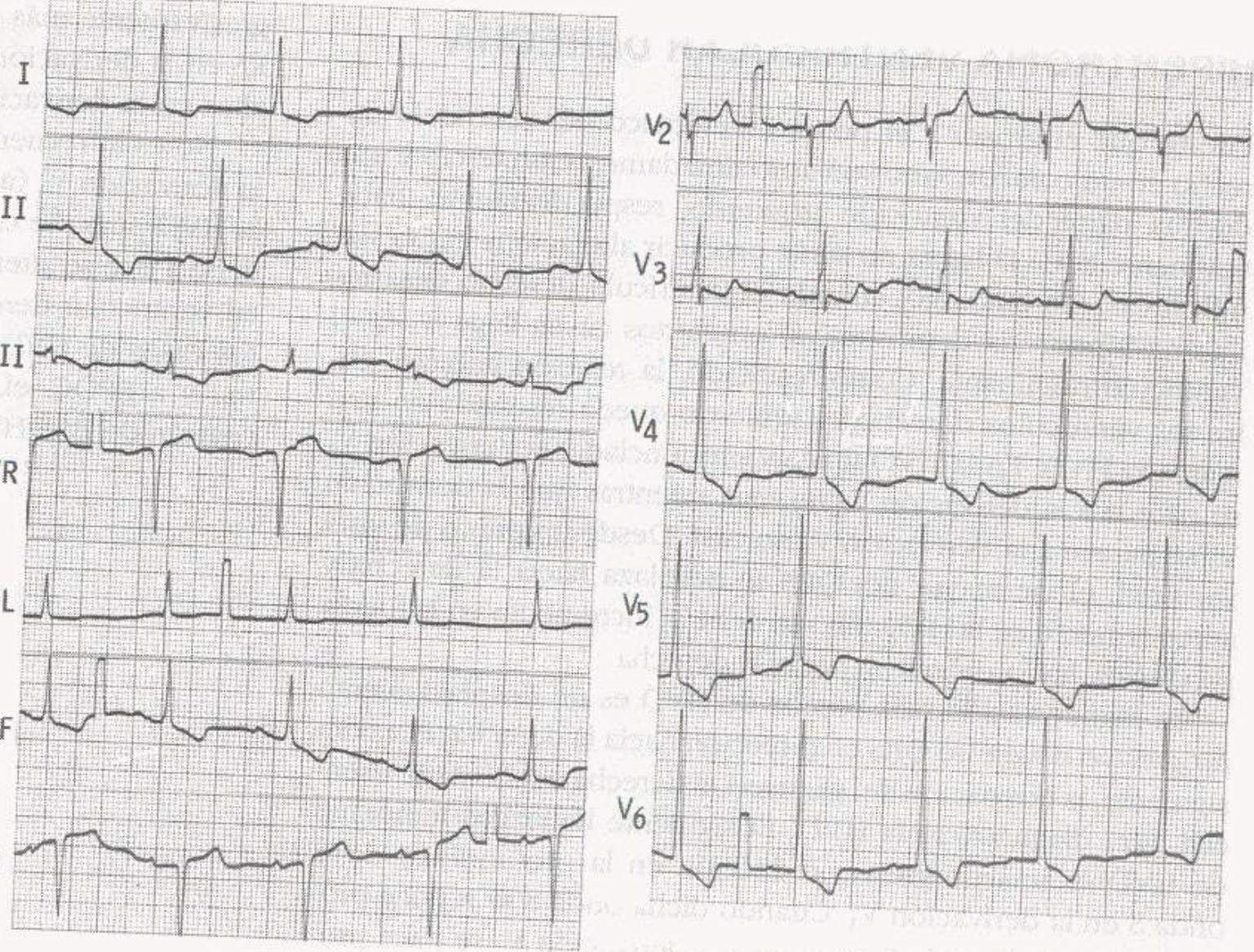
V2

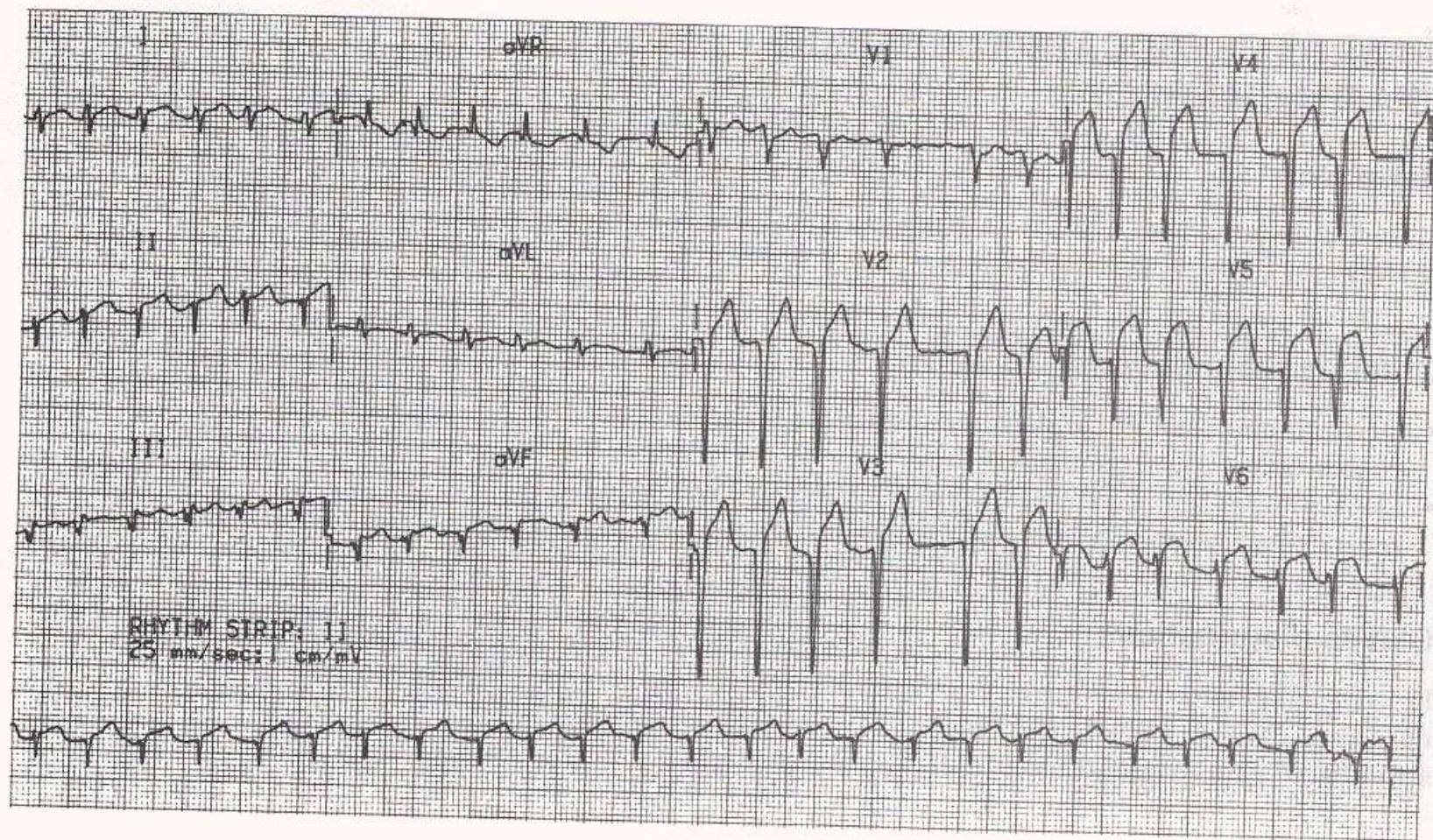
V3

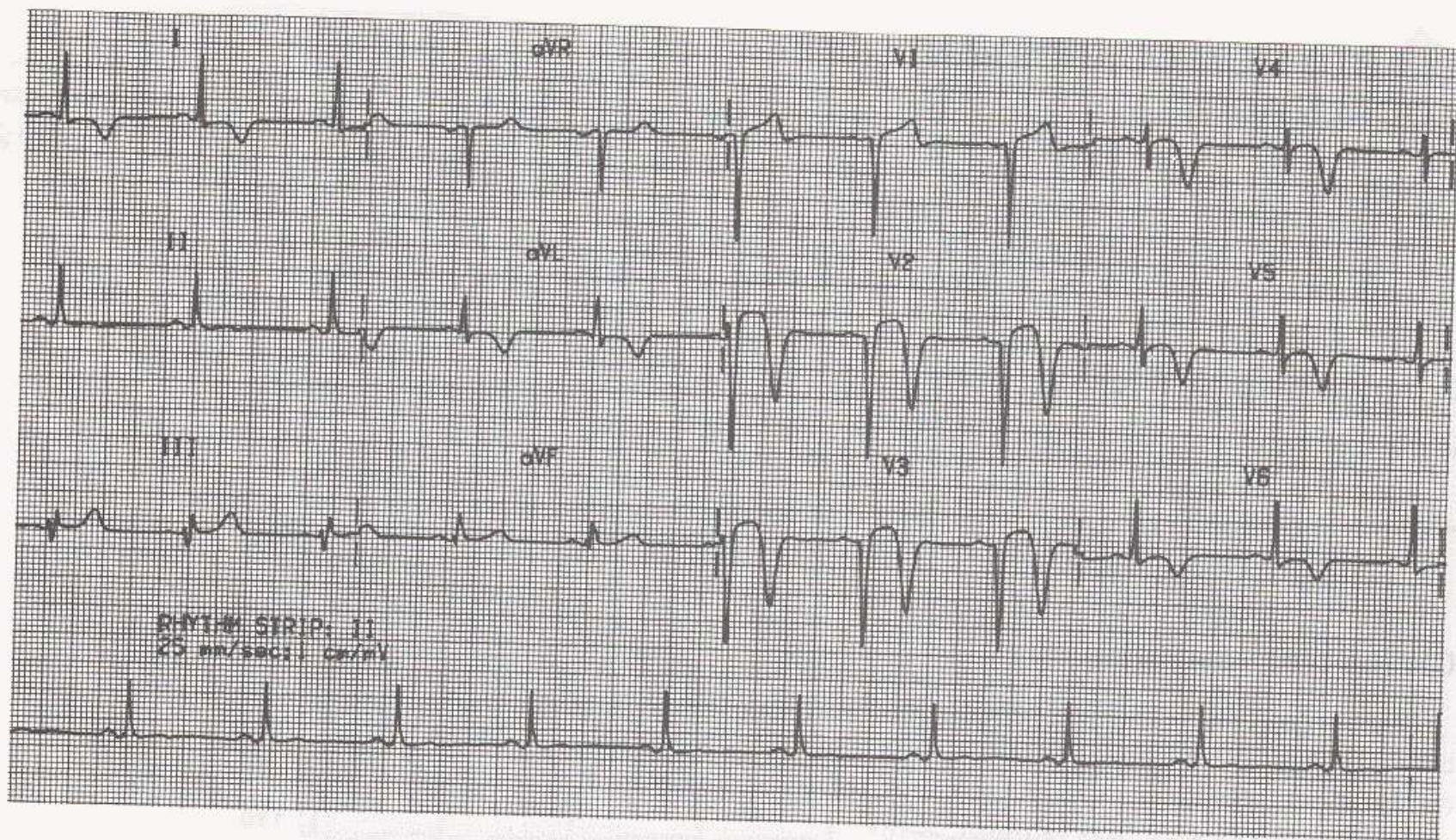
V4

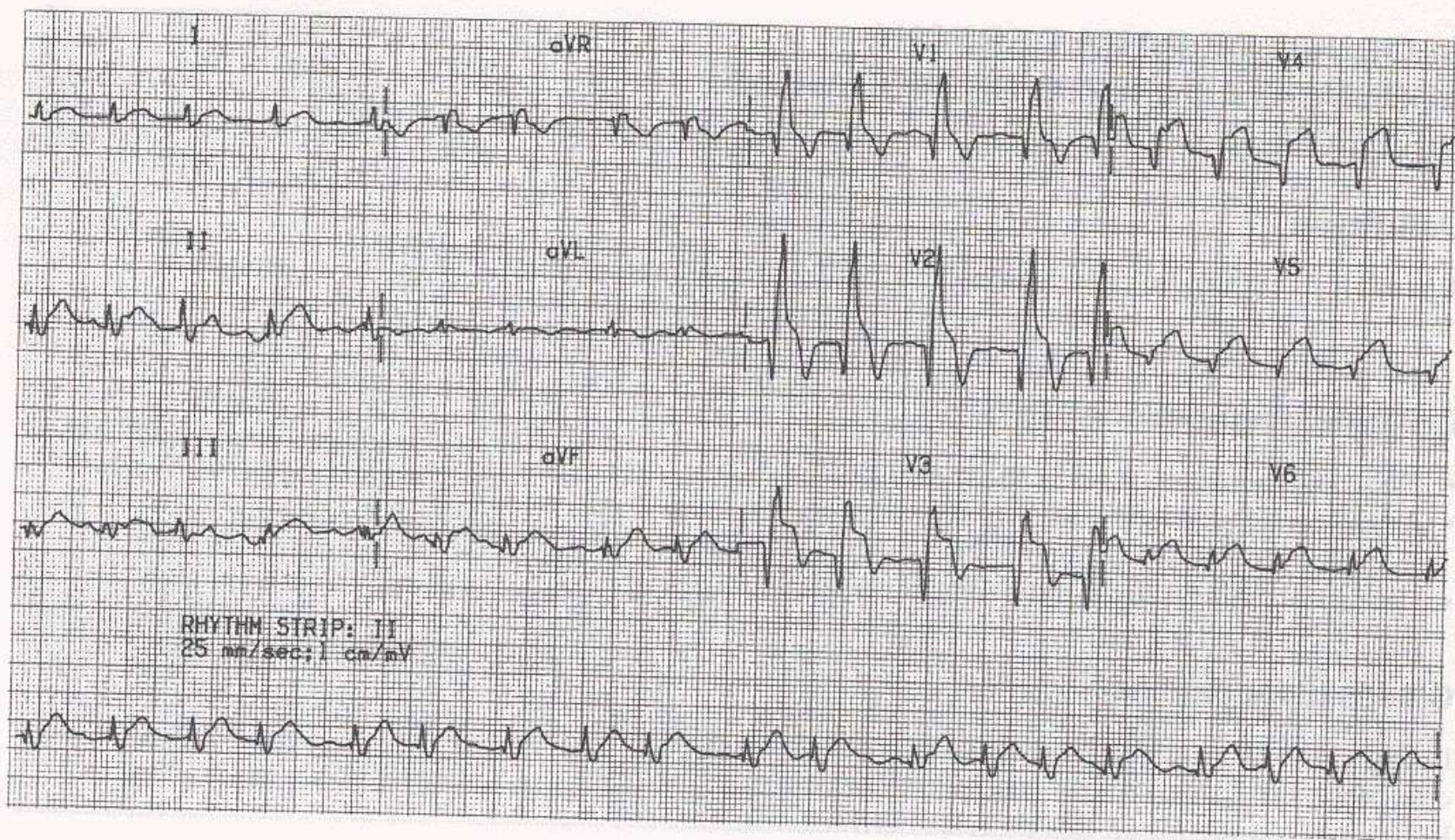
V5

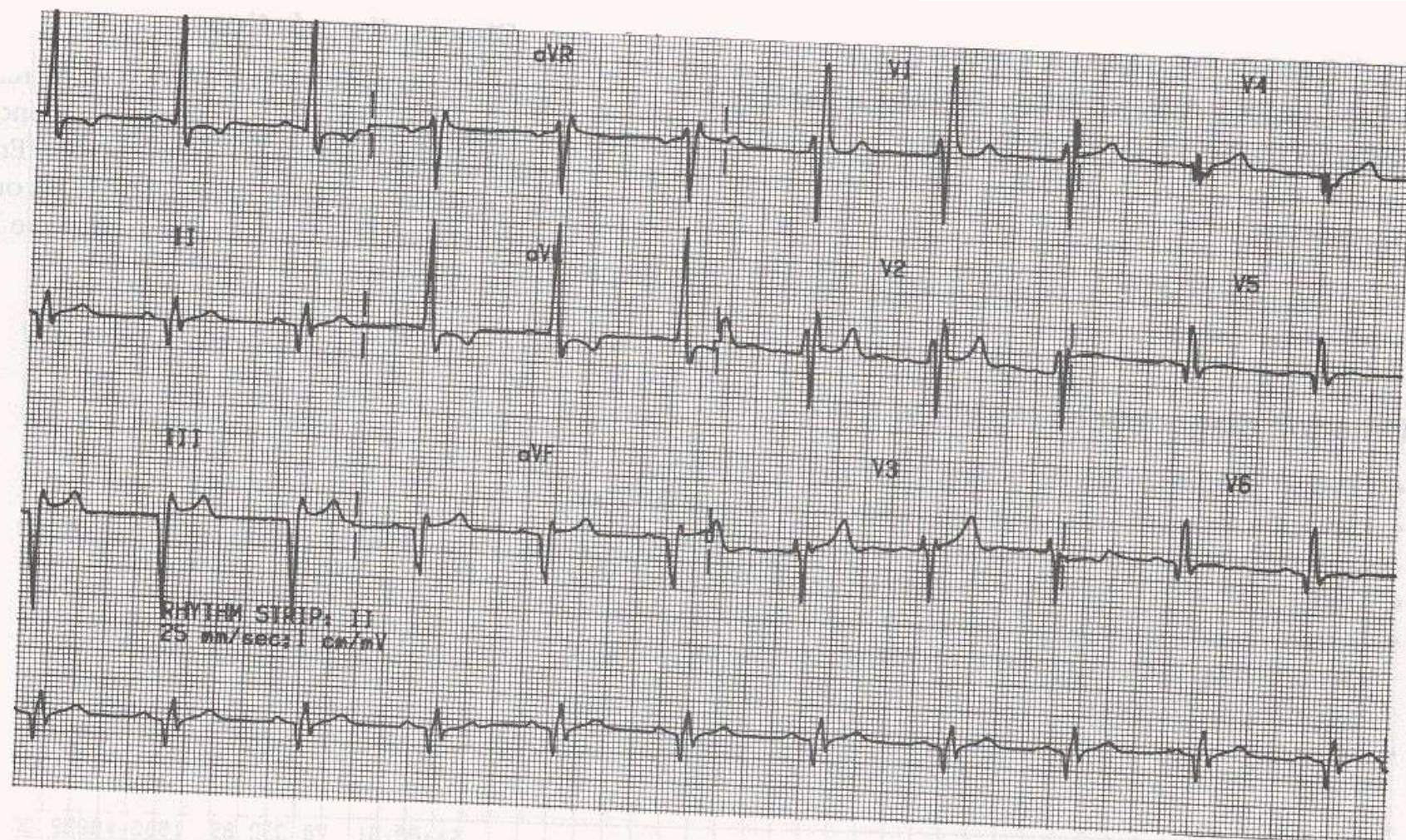
V6



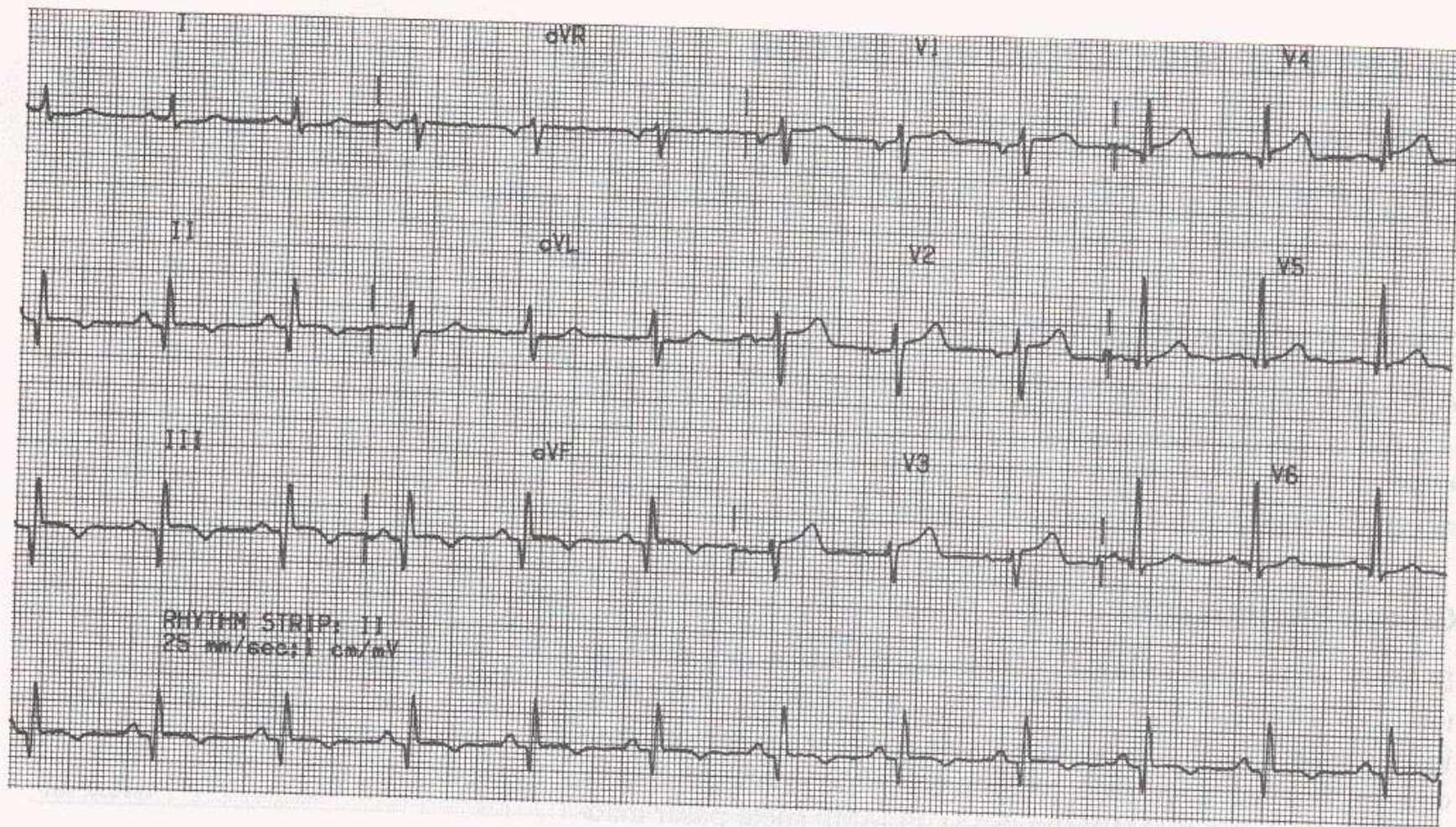


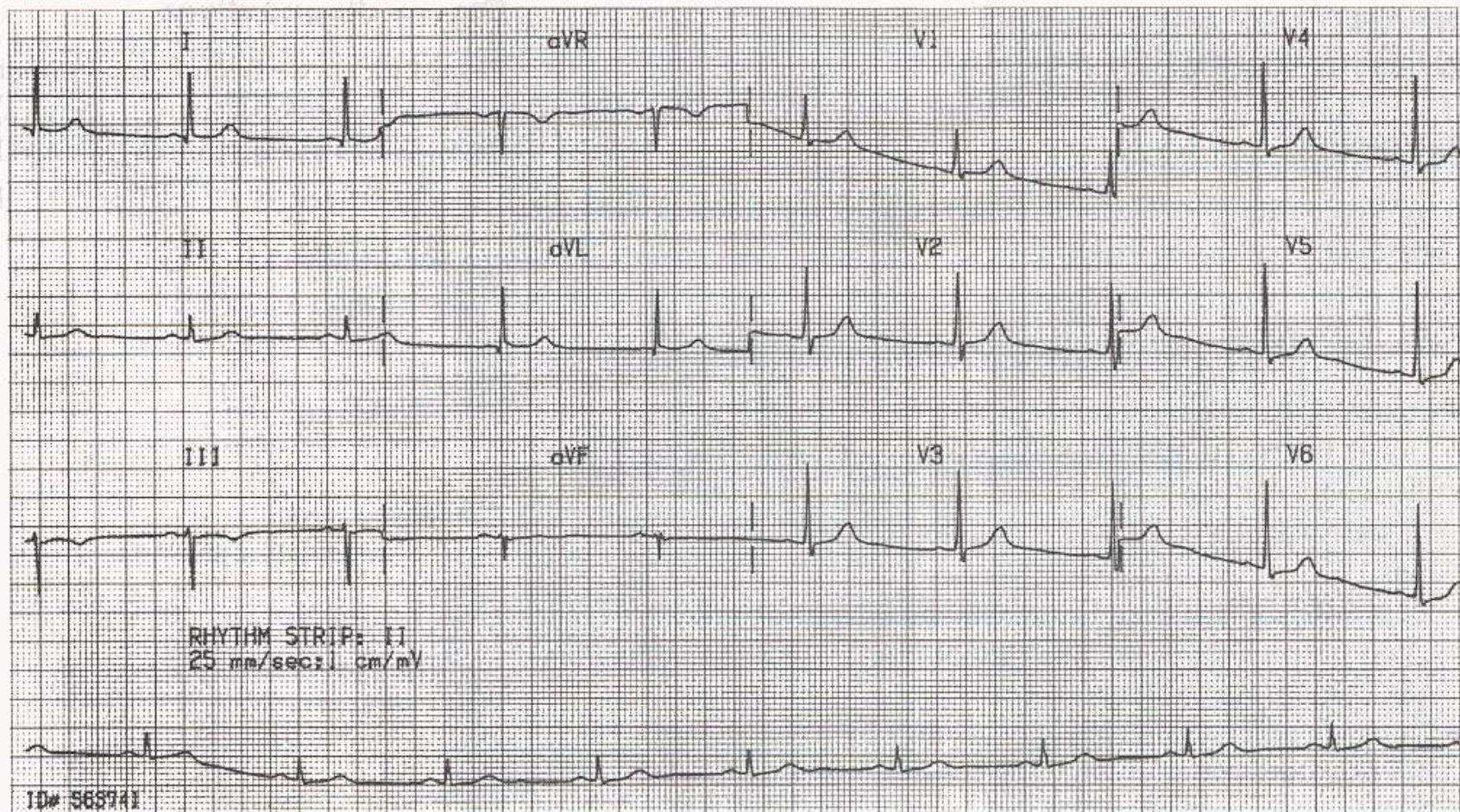


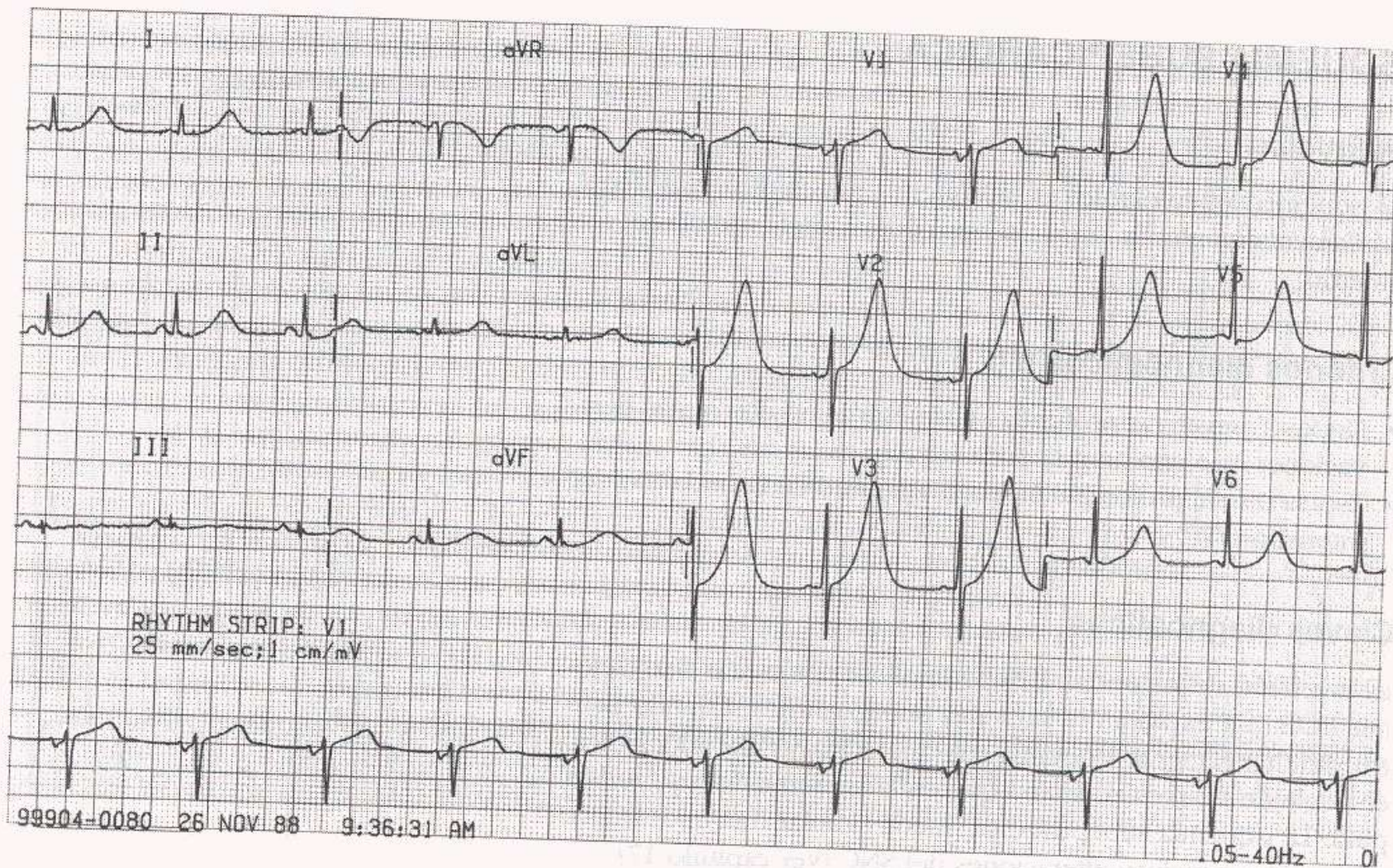




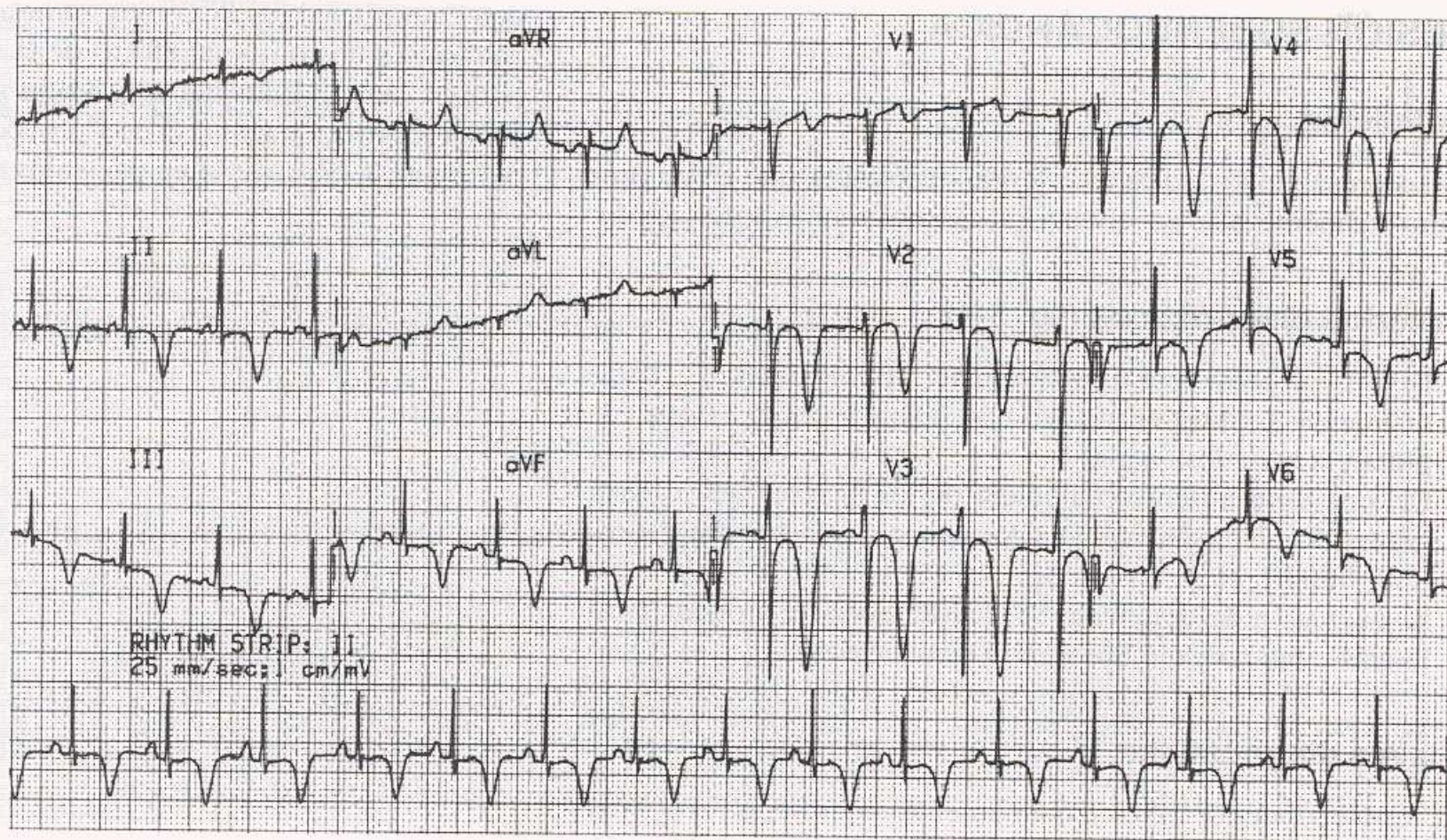
ECG 12-lead, 25 mm/sec, 1 cm/mV

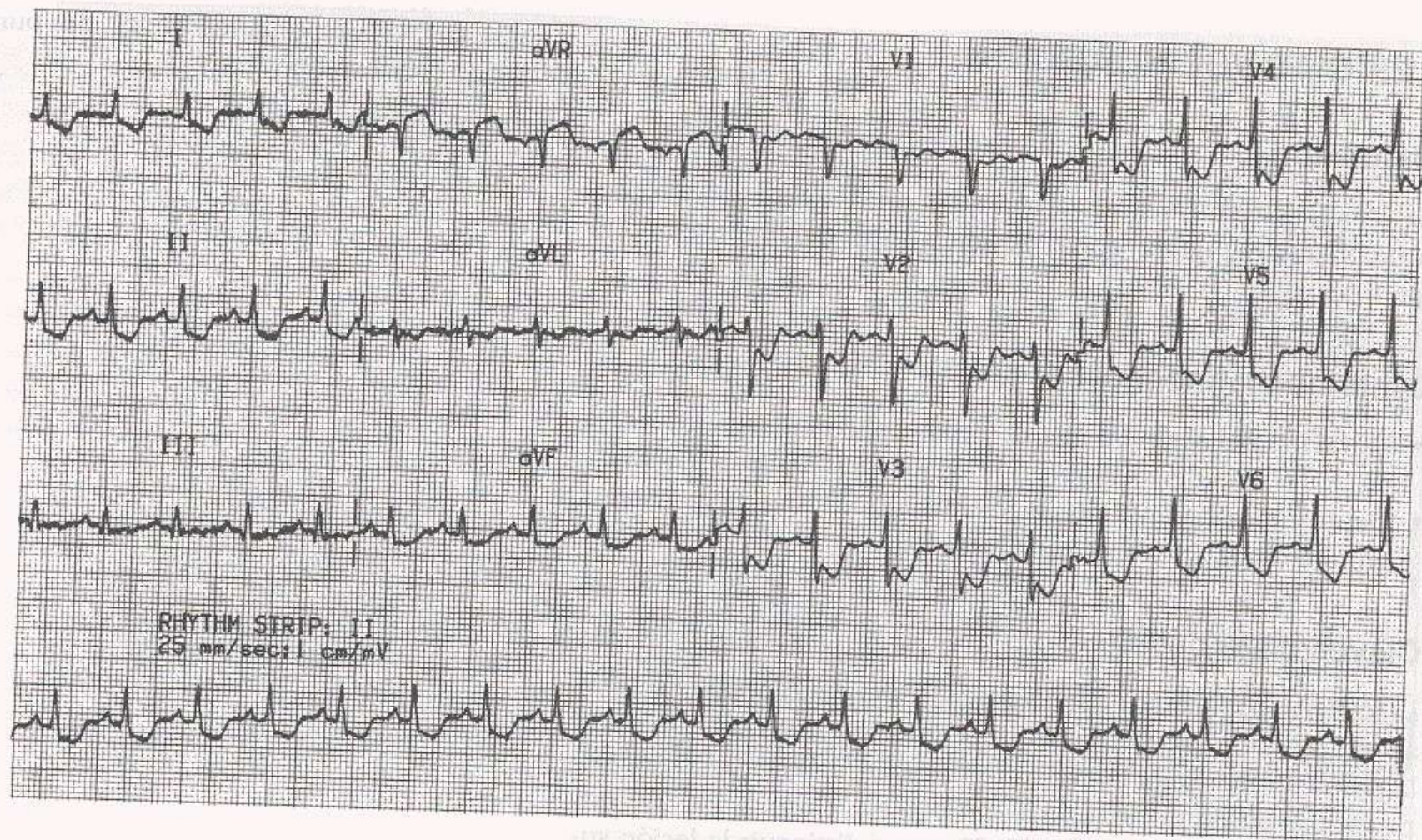




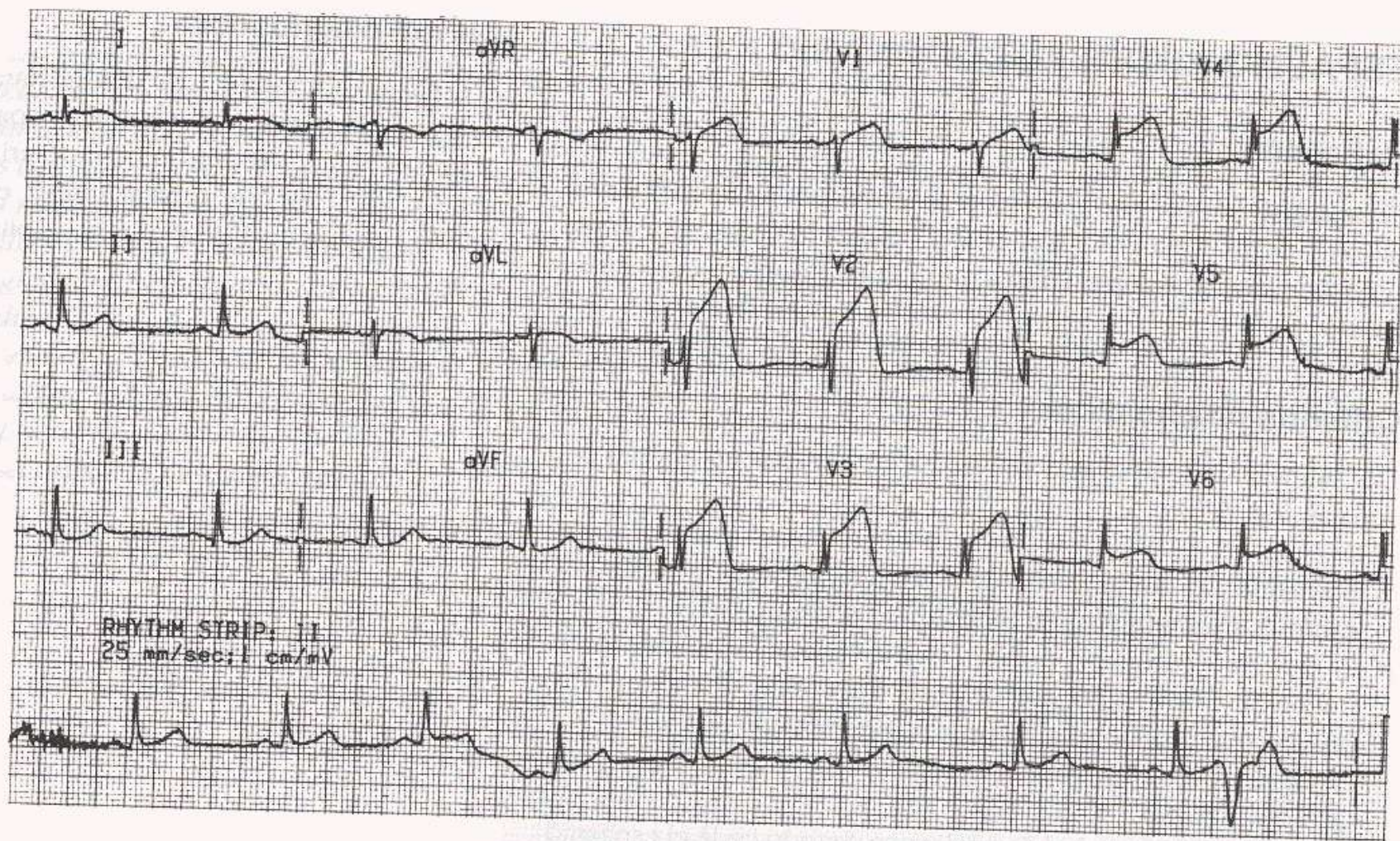


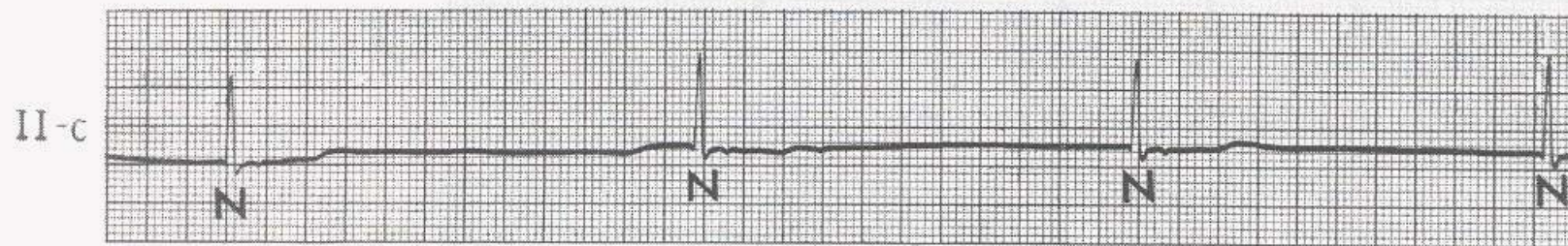
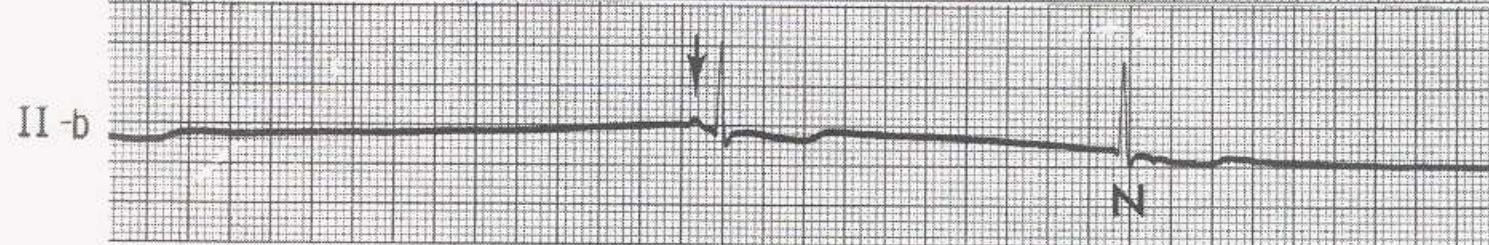

ca

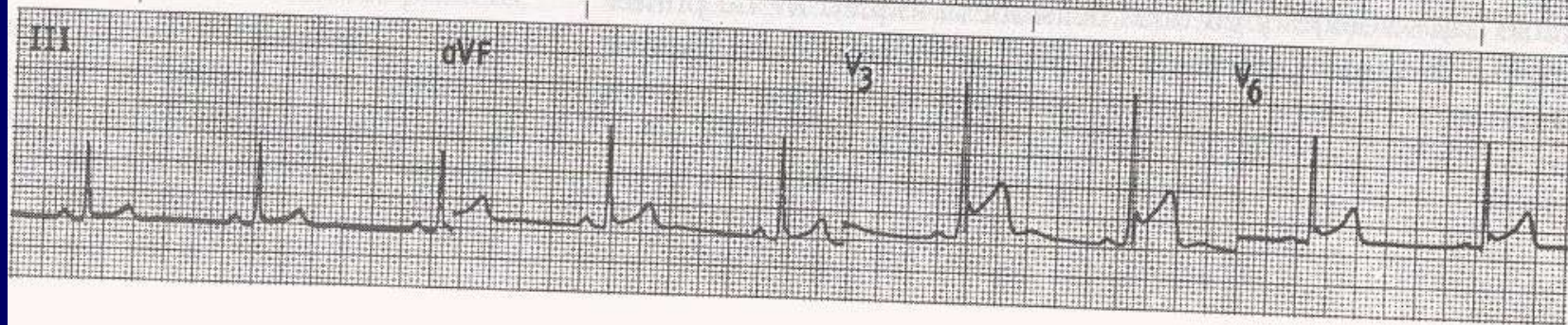
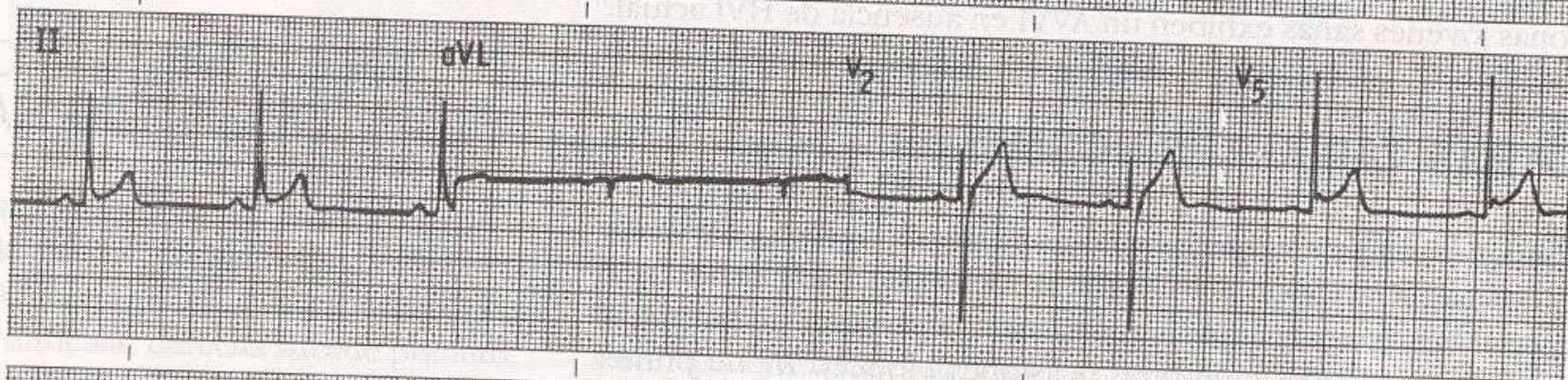
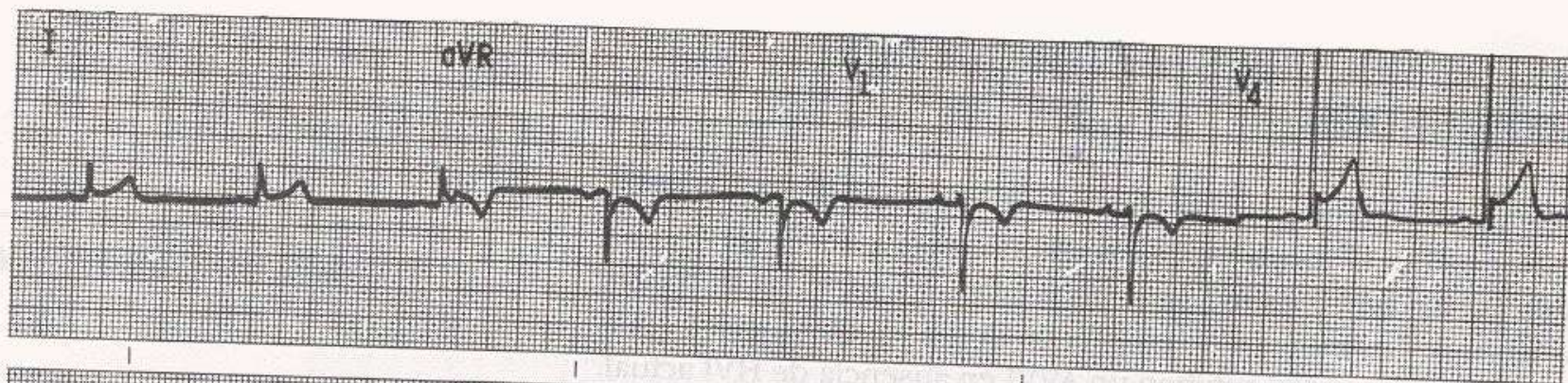




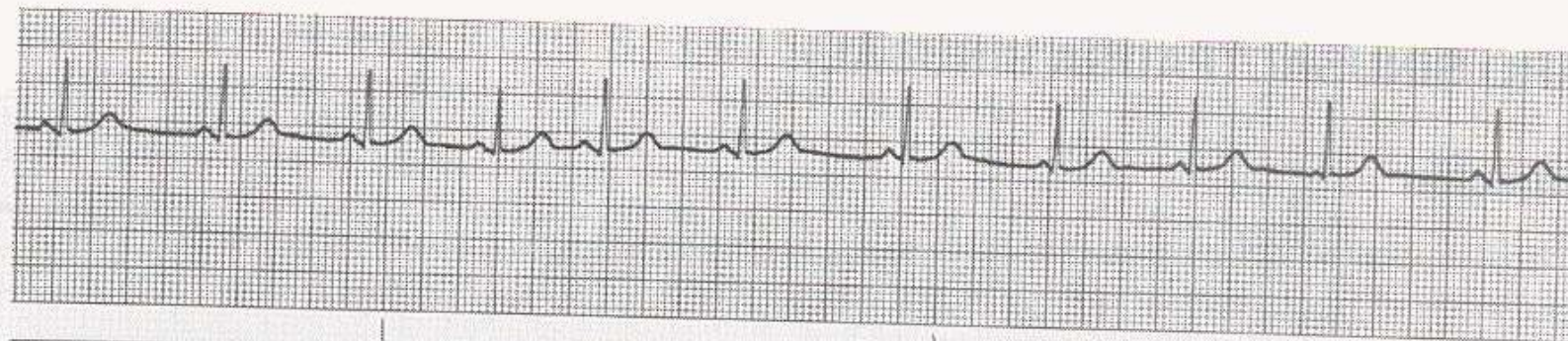
cardiac arrest (see chapter 17). May not distinguish in lesion su-
cardiac arrest (see chapter 17). May not distinguish in lesion su-



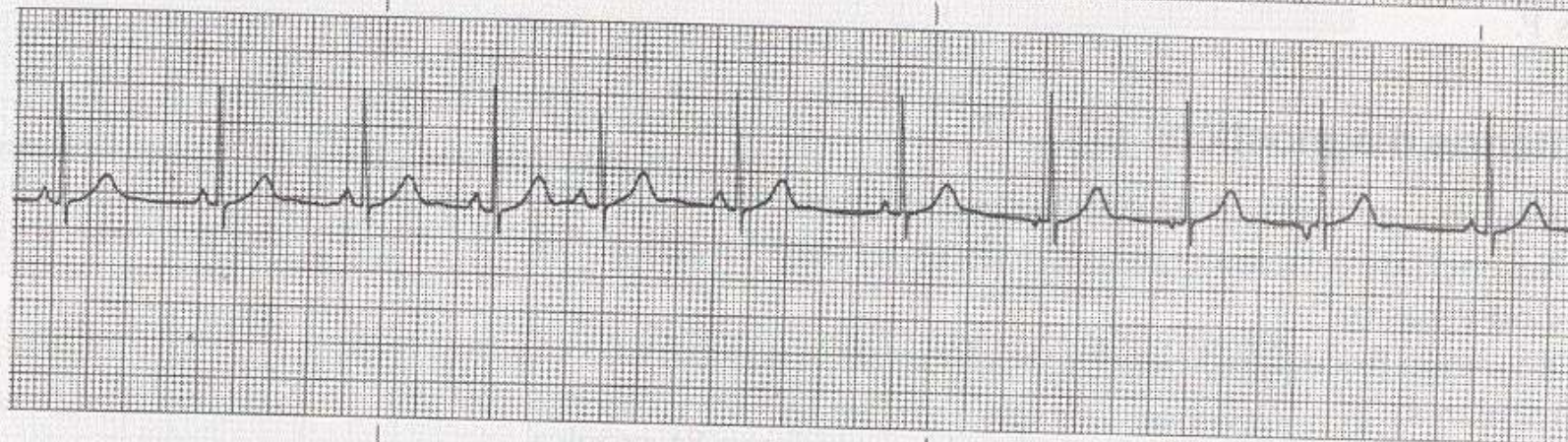




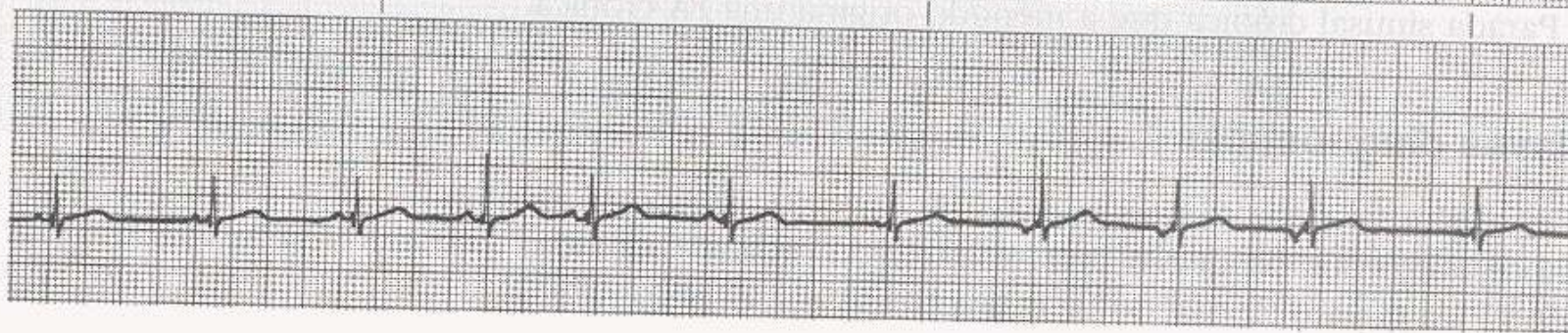
I

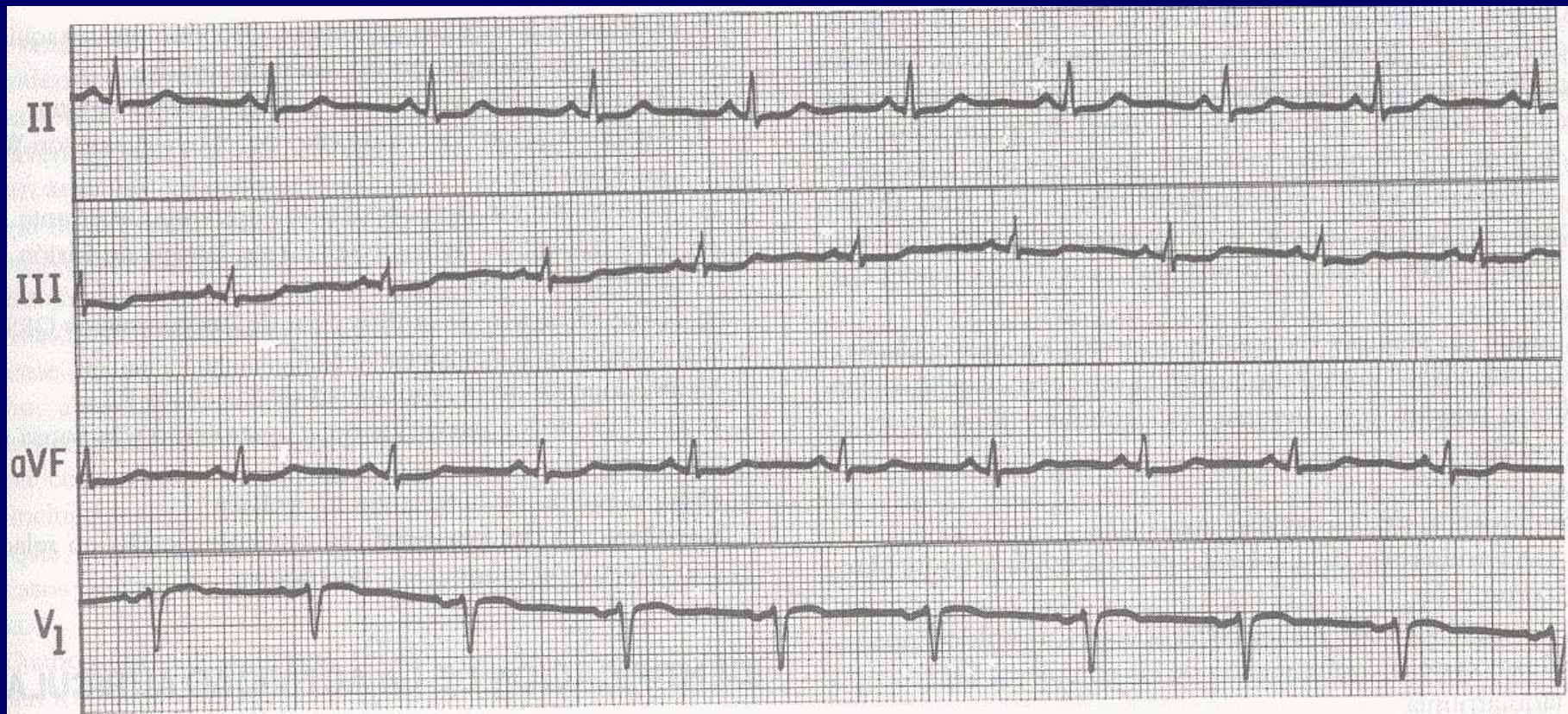


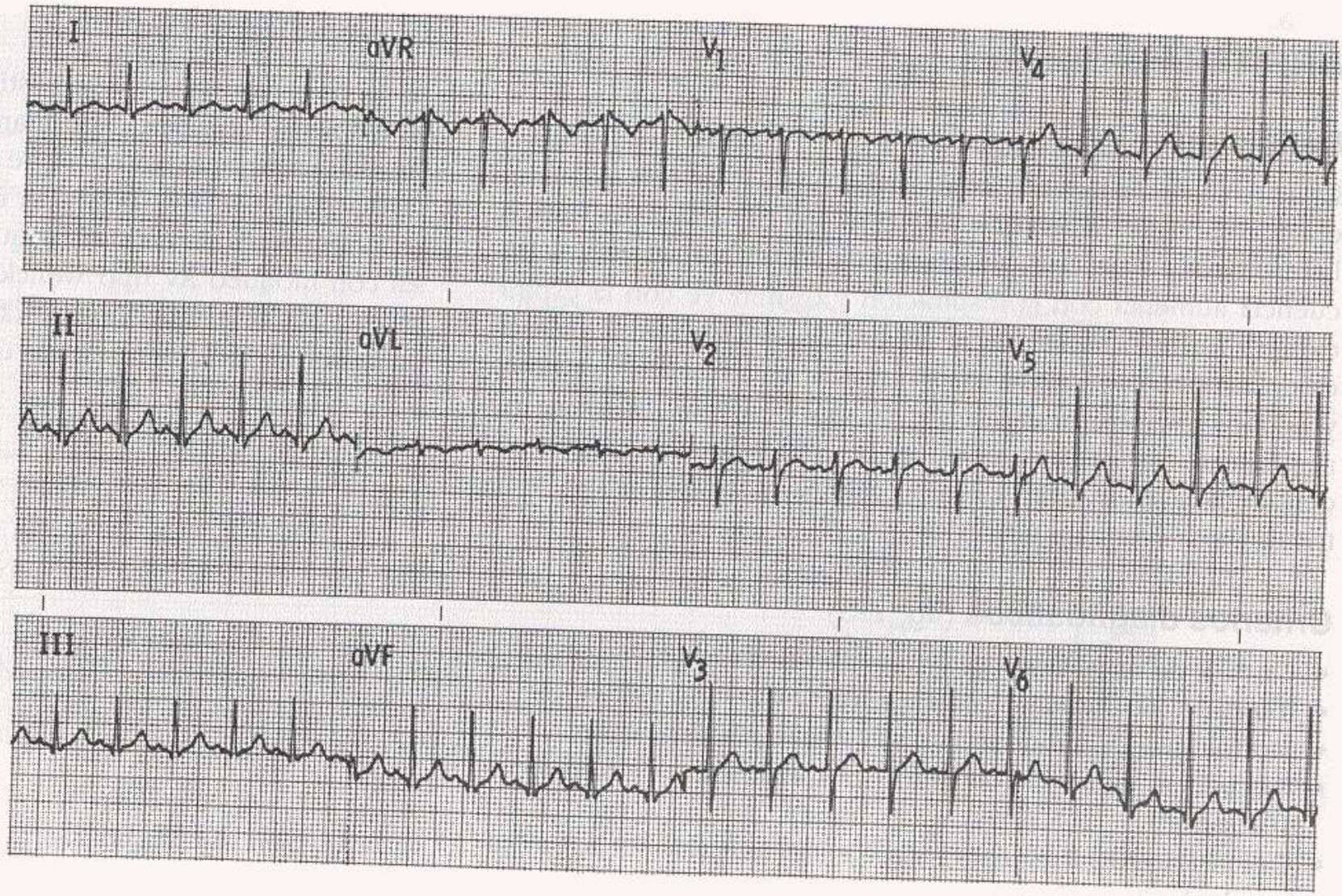
II

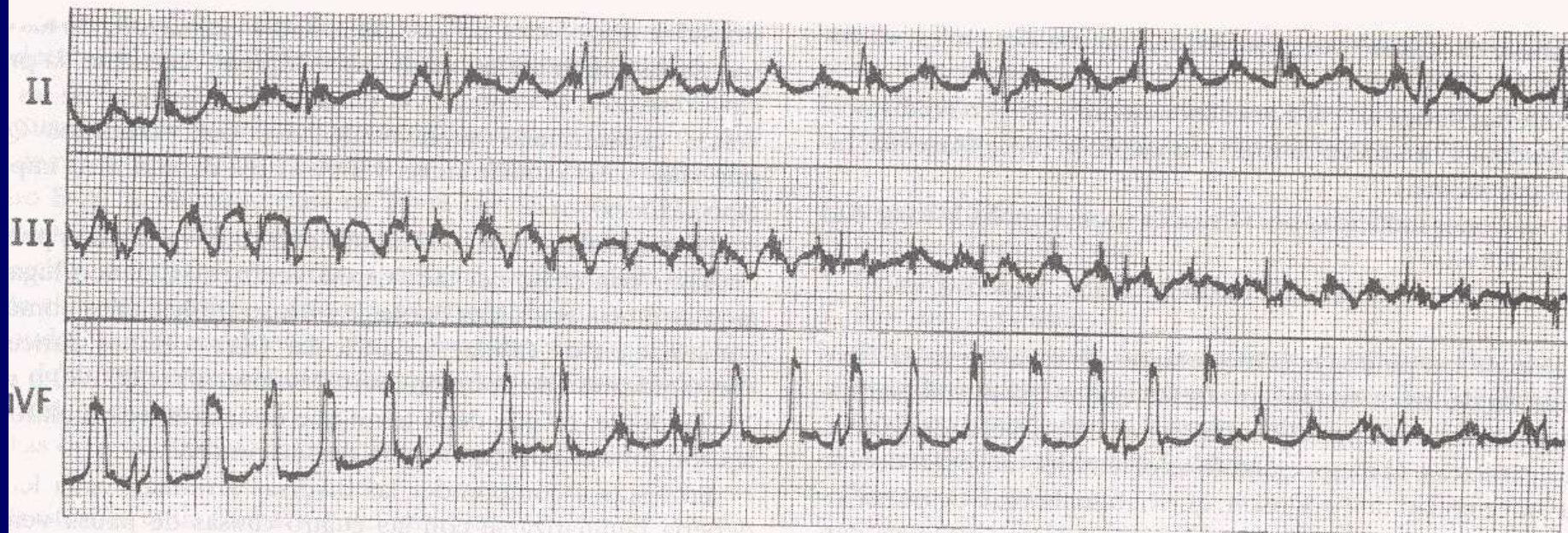


III

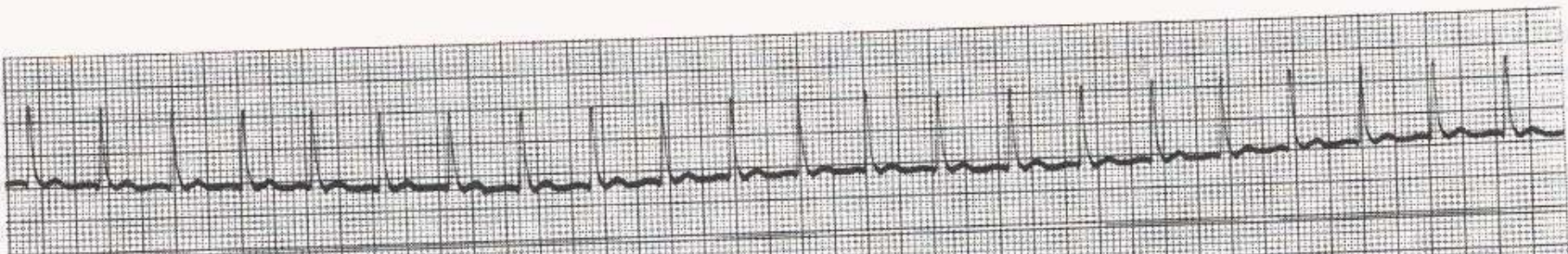




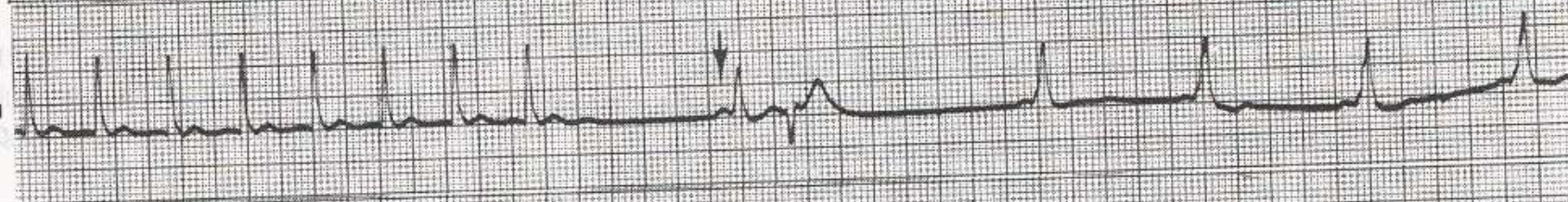




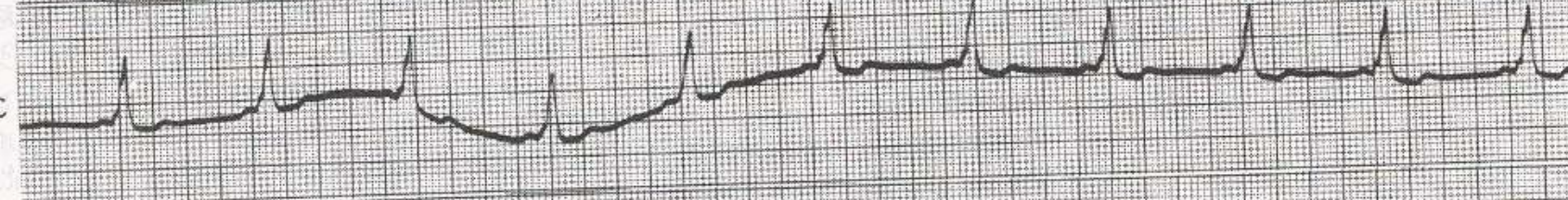
II-a



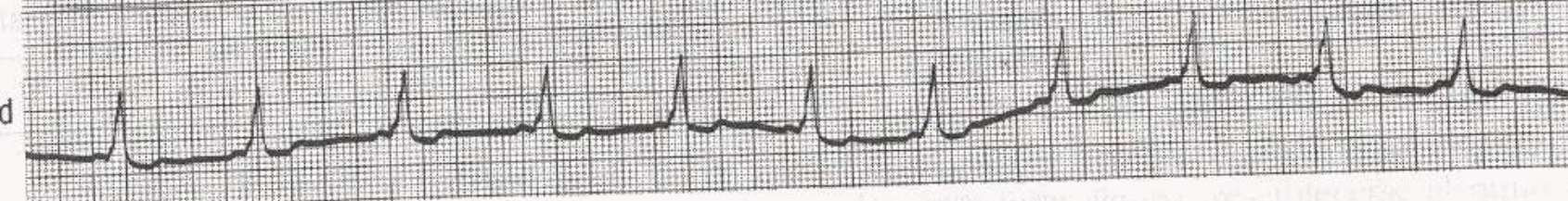
II-b



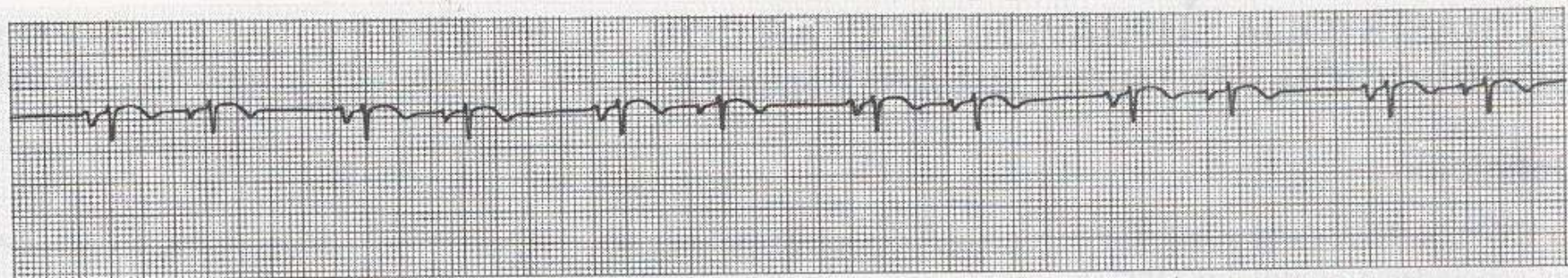
II-c



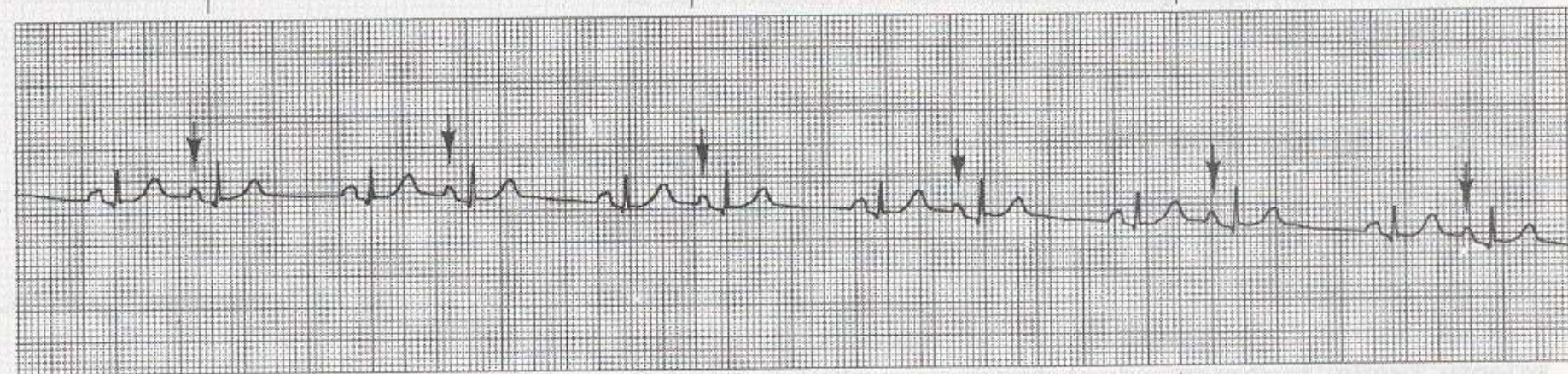
II-d



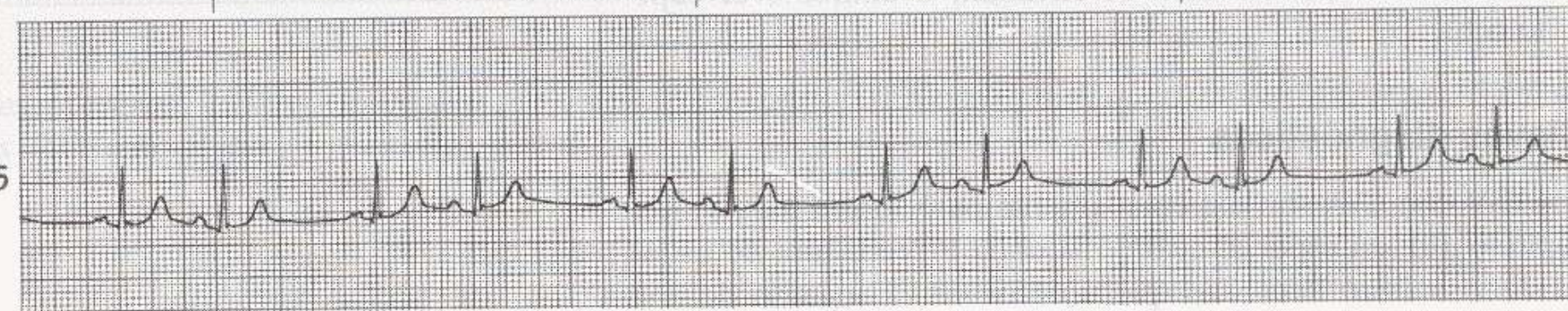
V₁

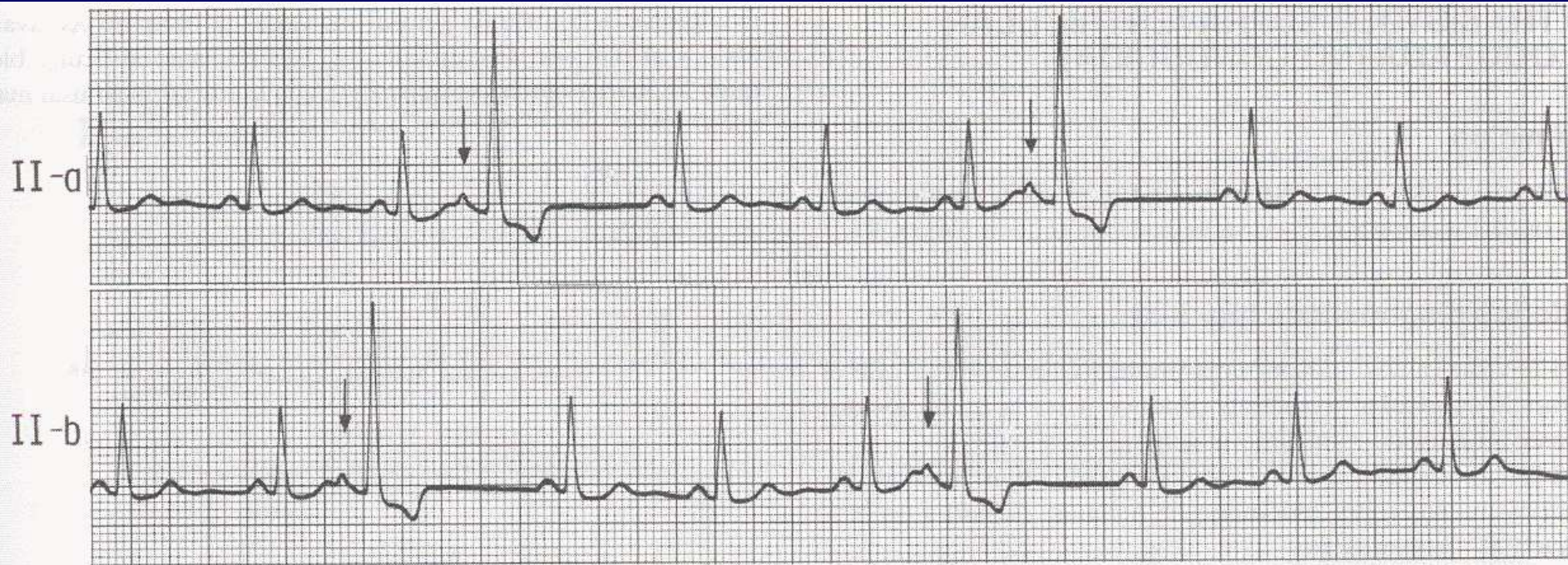

II

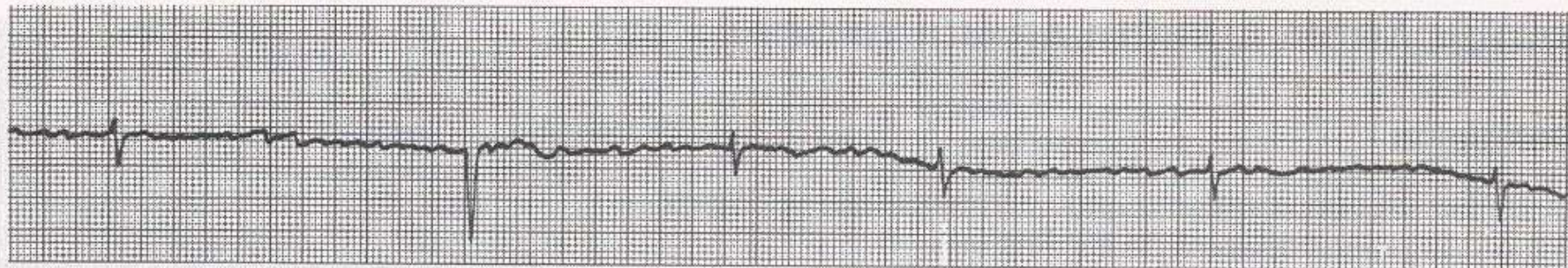


V₅

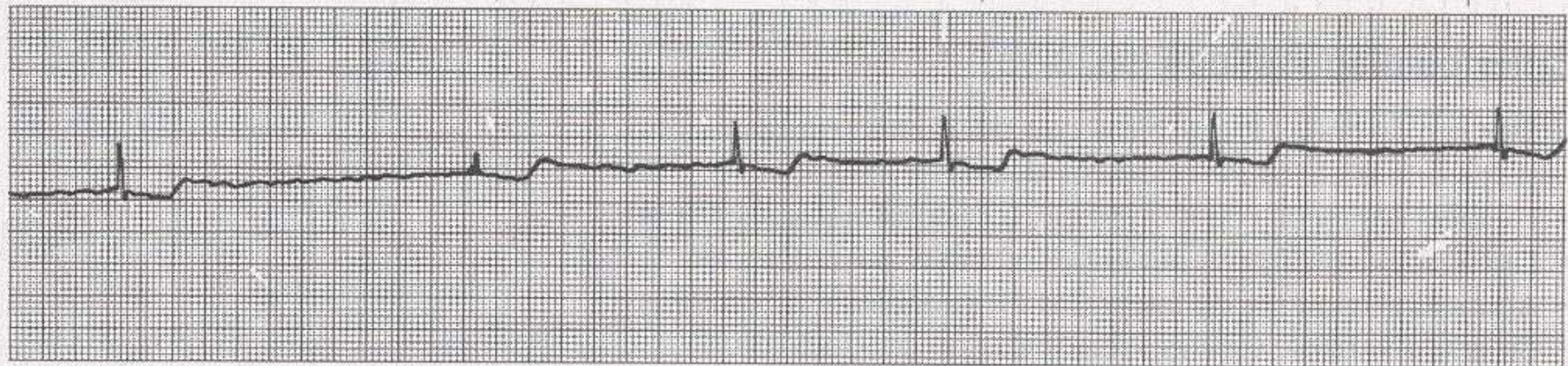




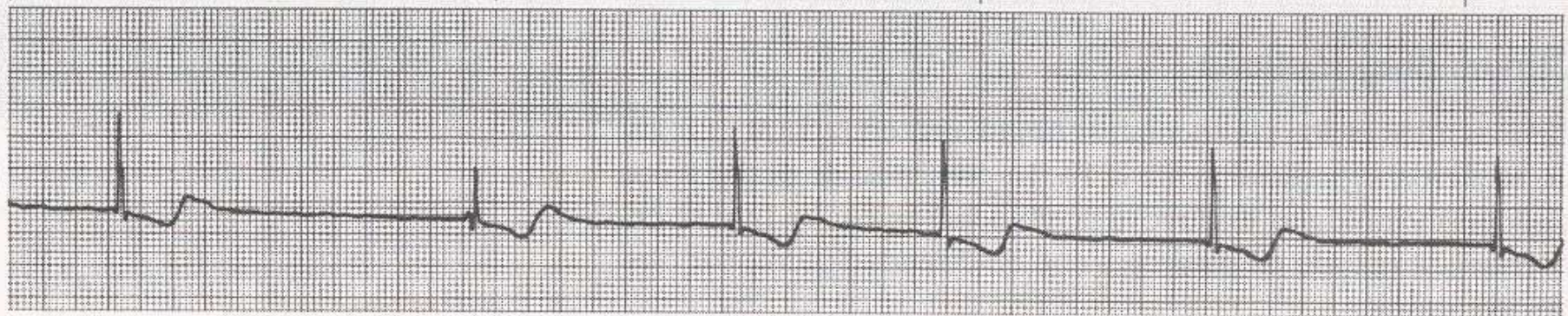
V₁



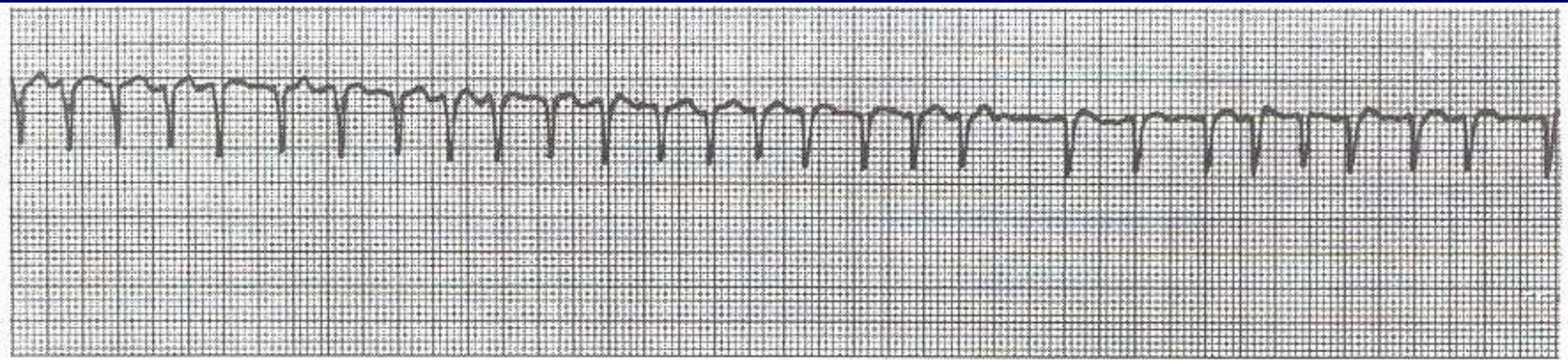
II



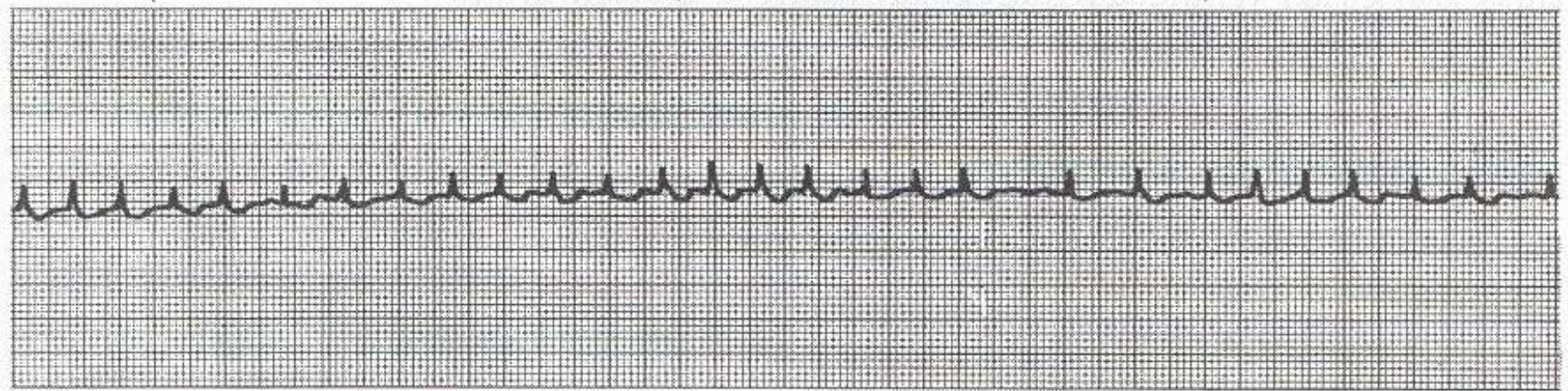
V₅



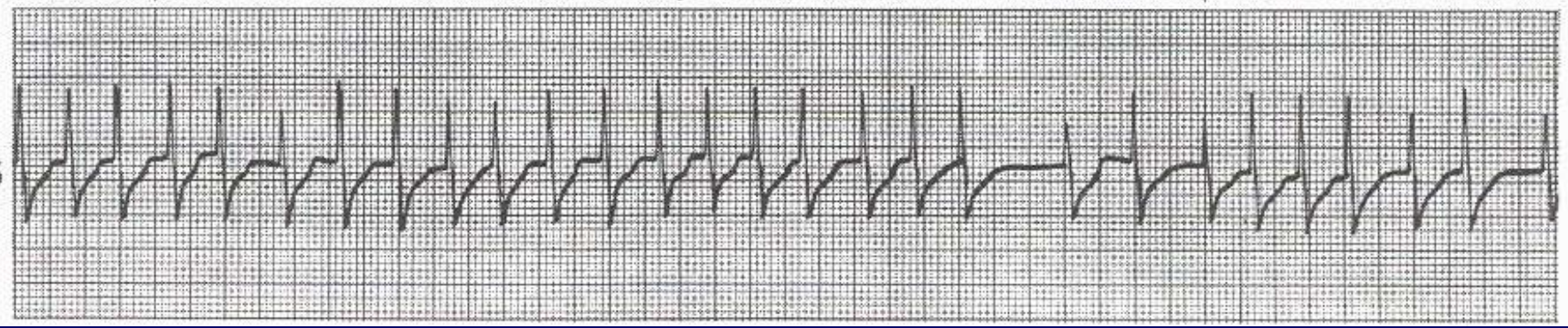
V₁

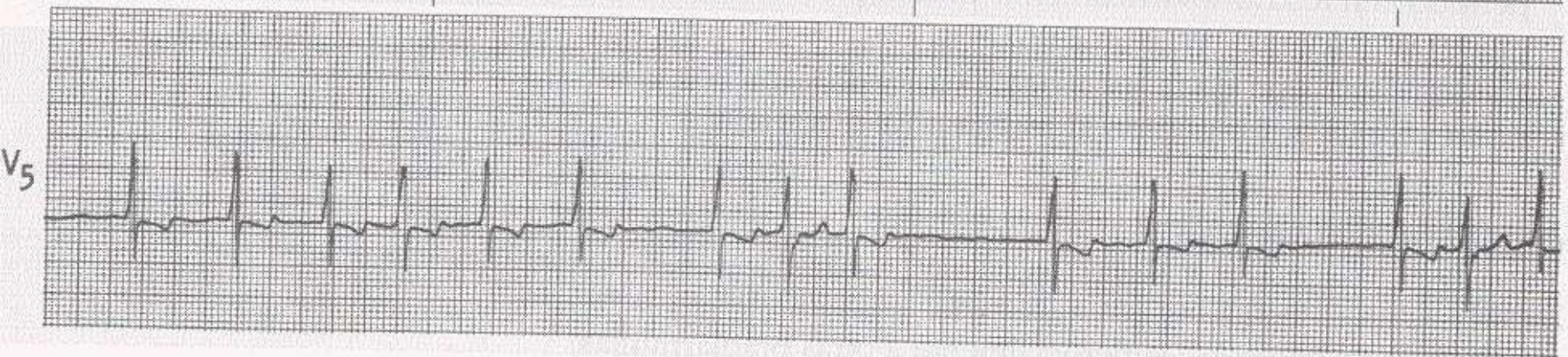
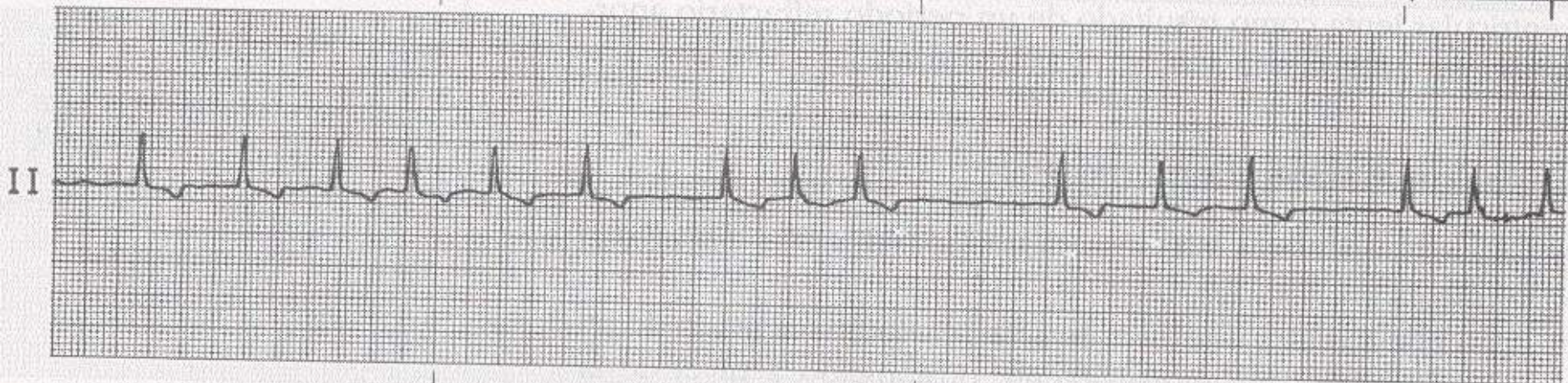
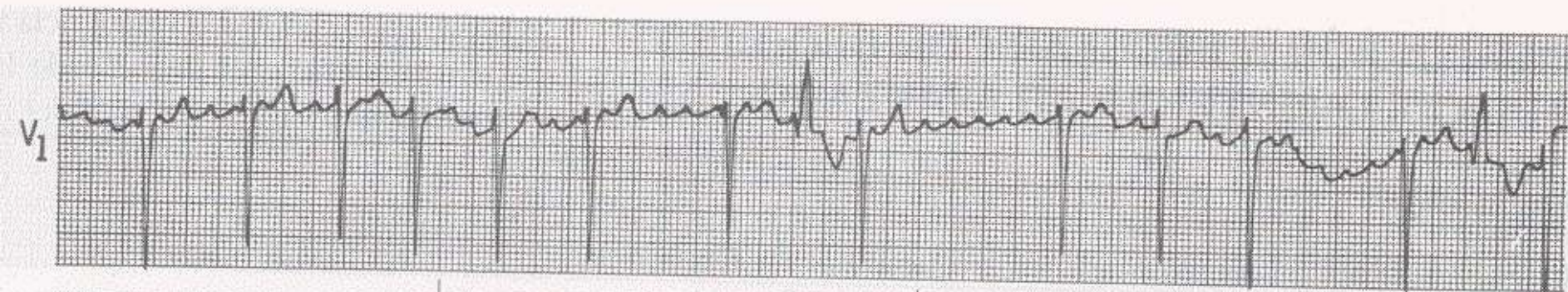


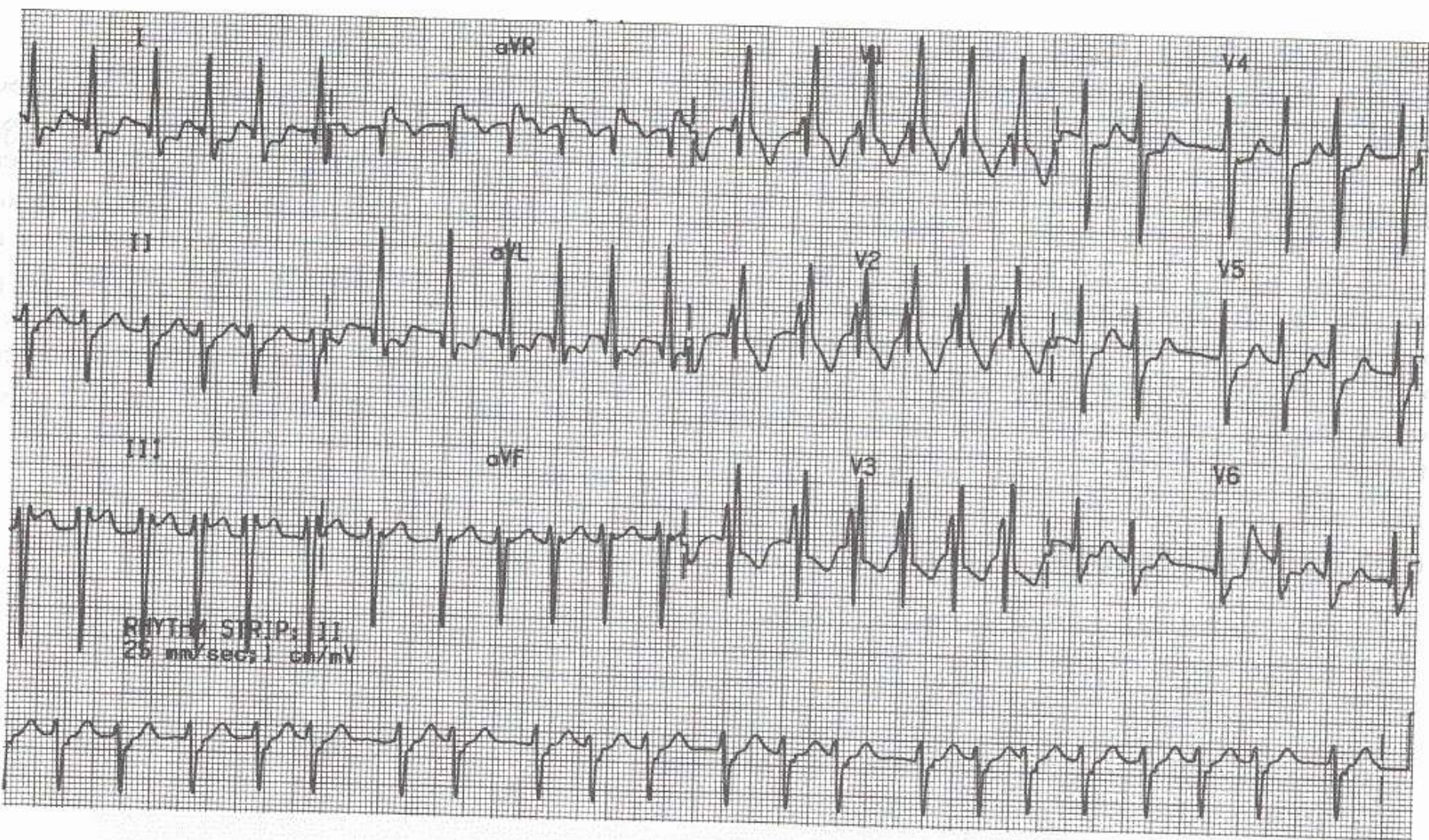
II

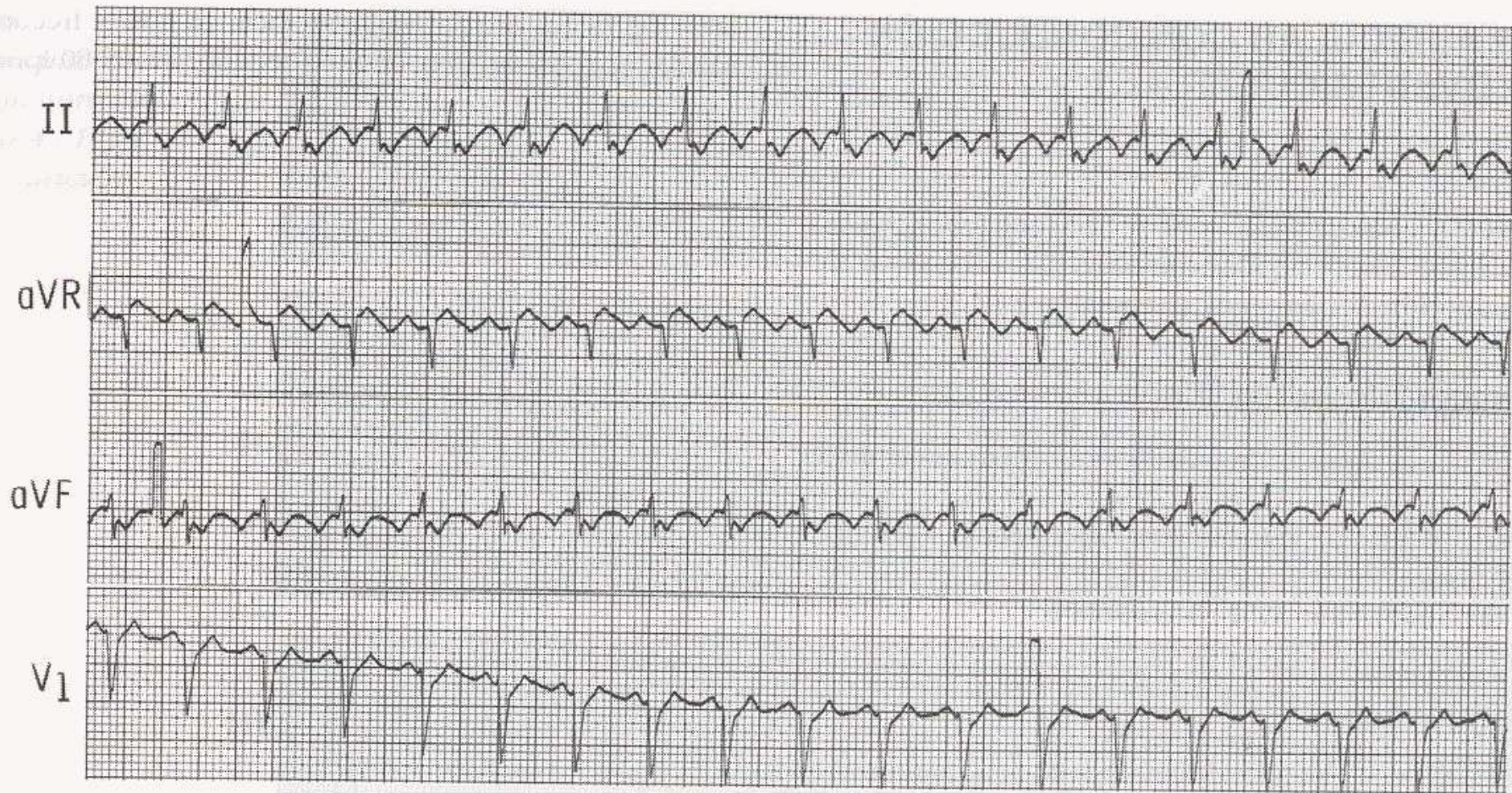


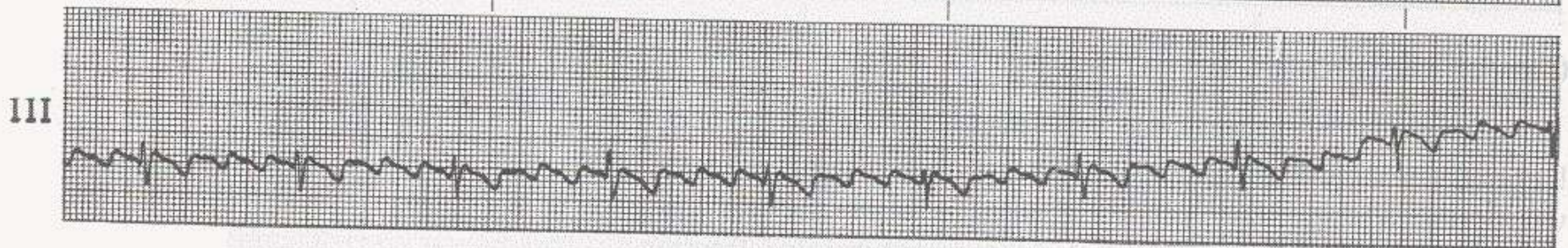
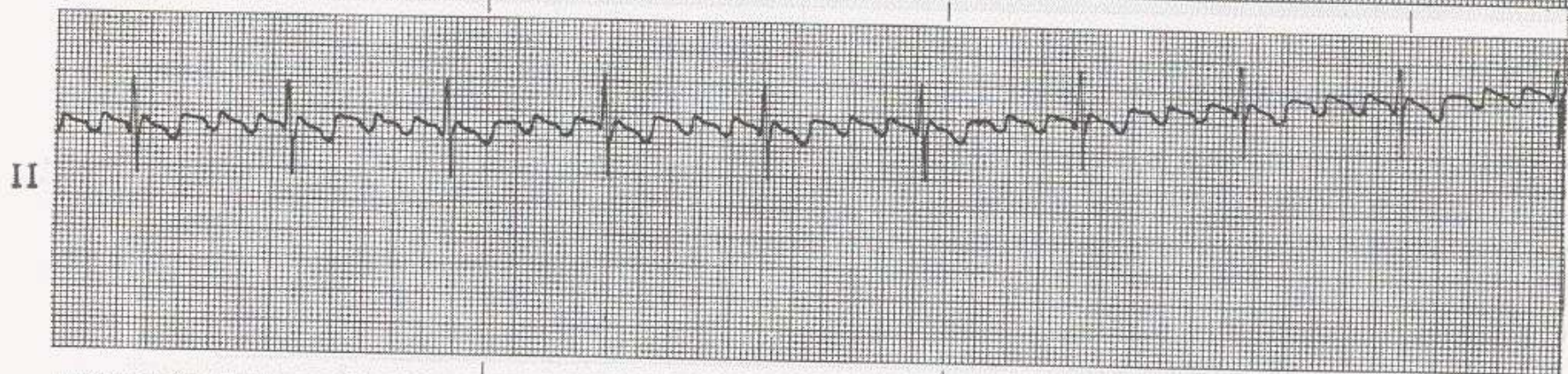
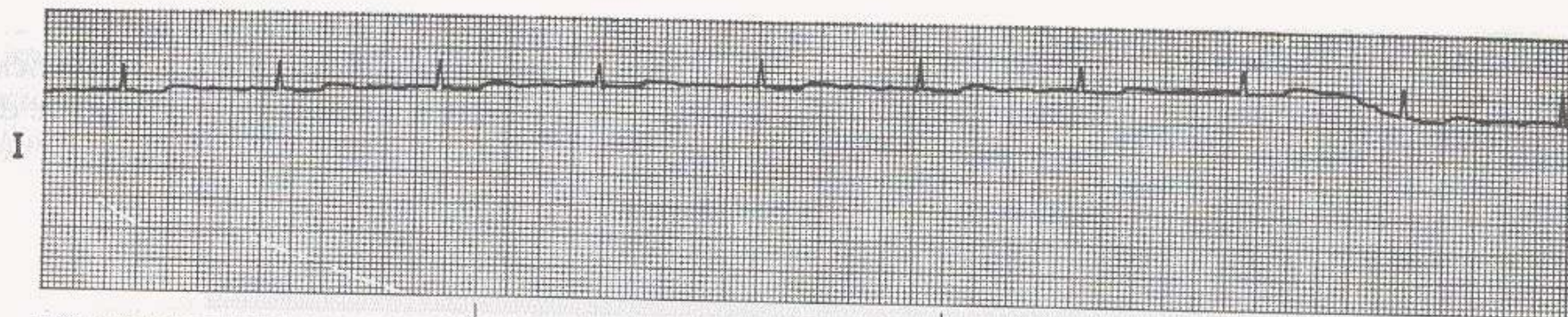
V₅

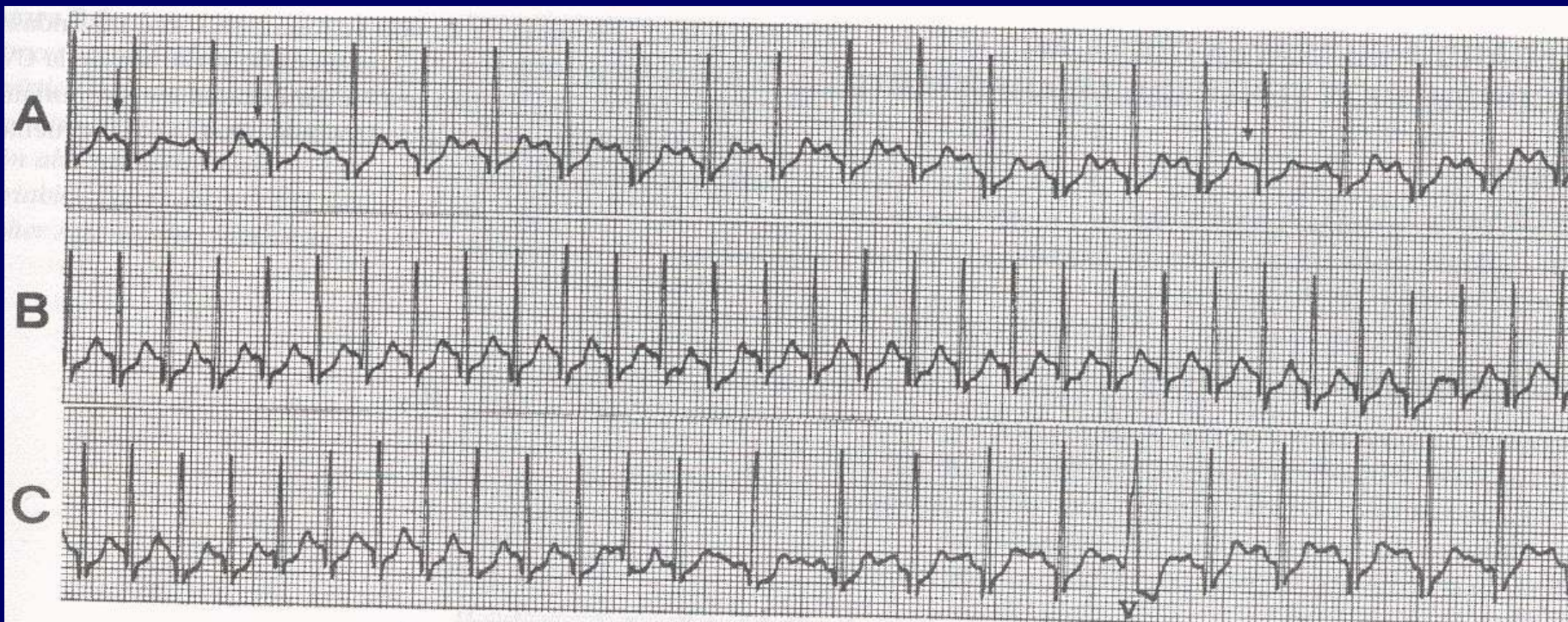


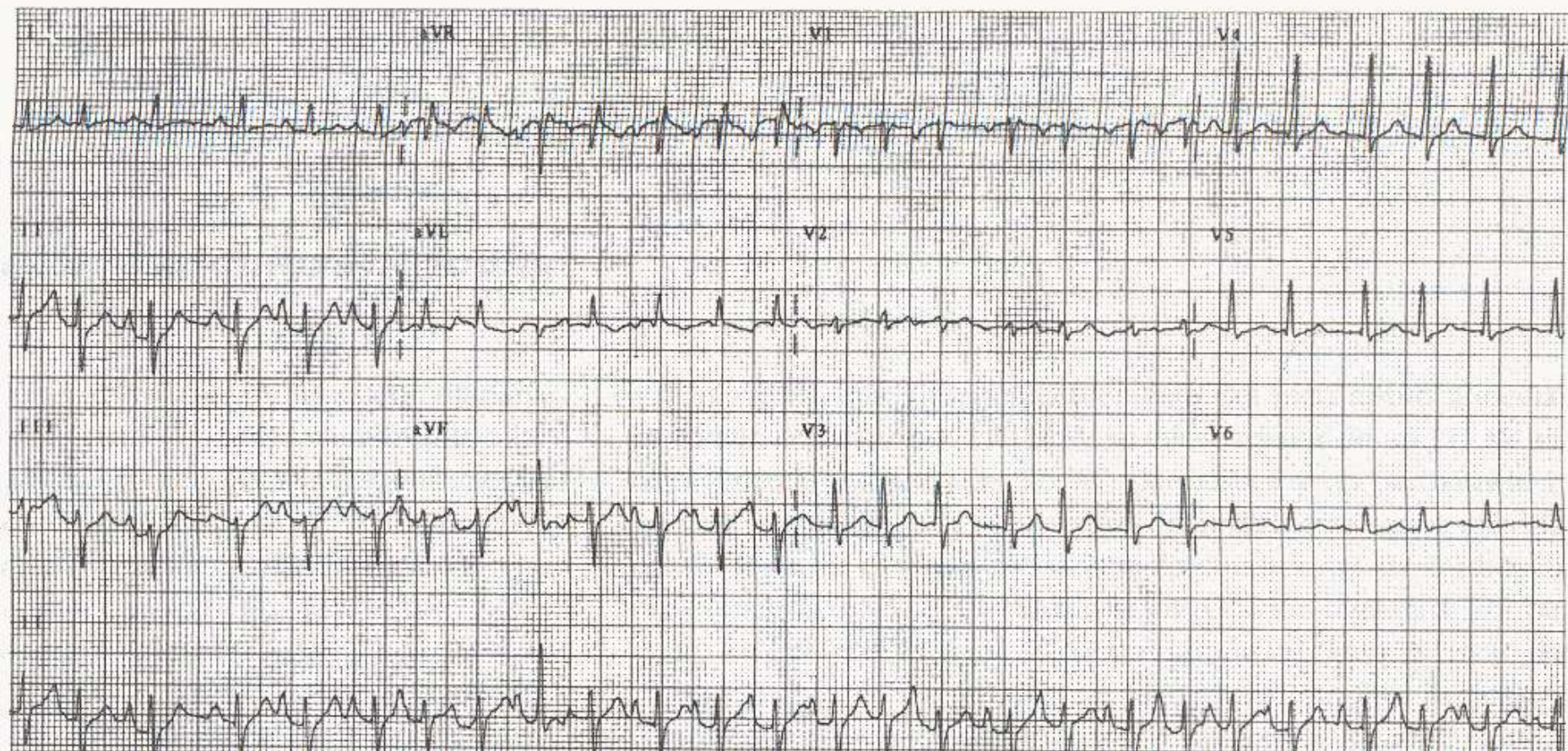




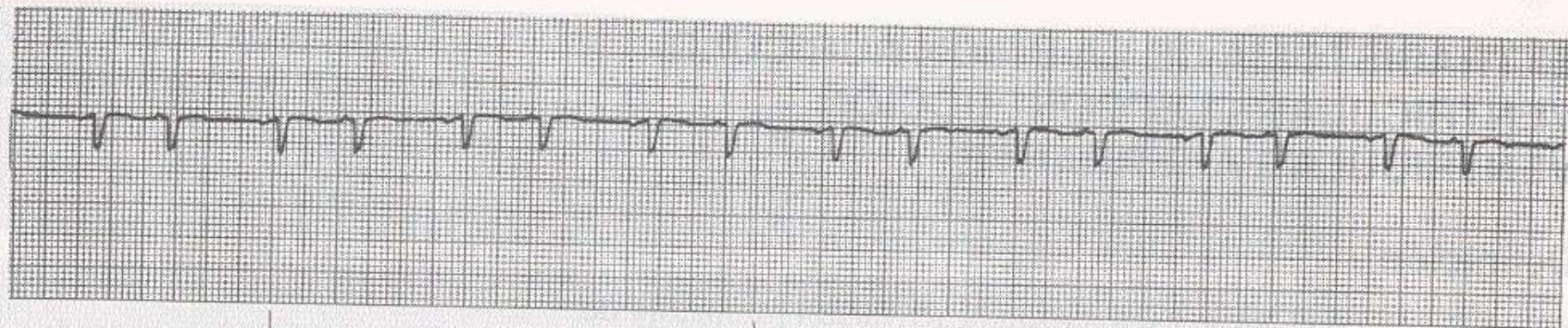




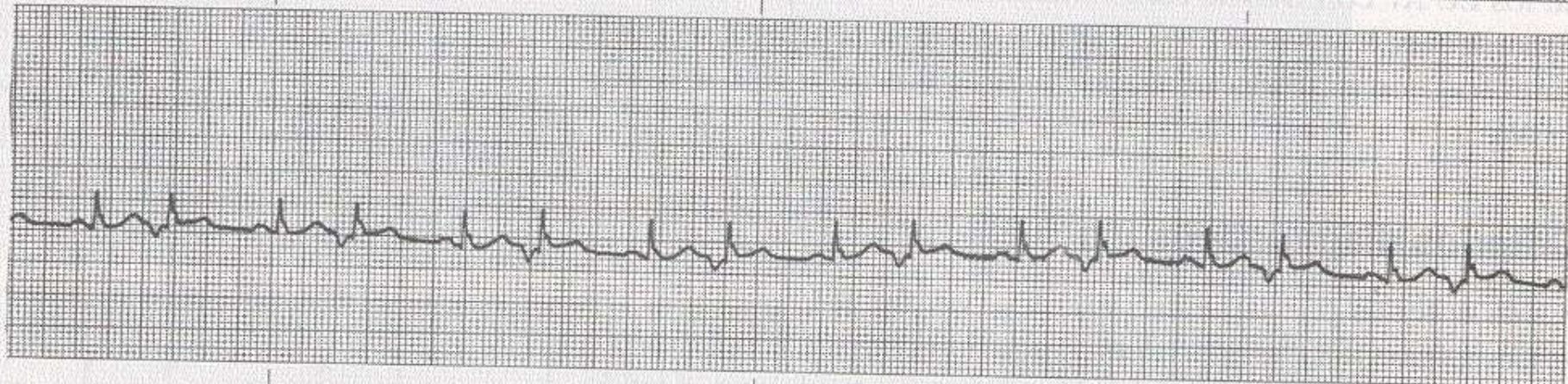




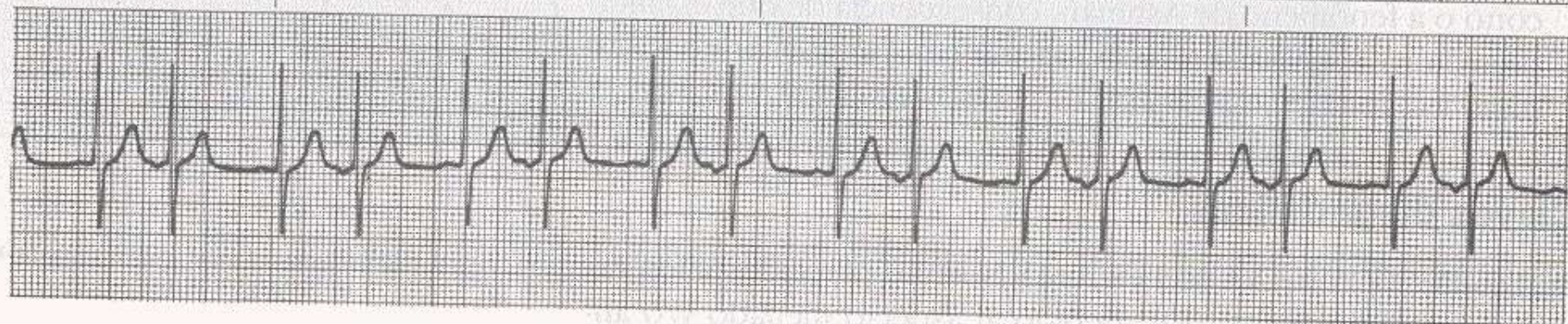
V₁

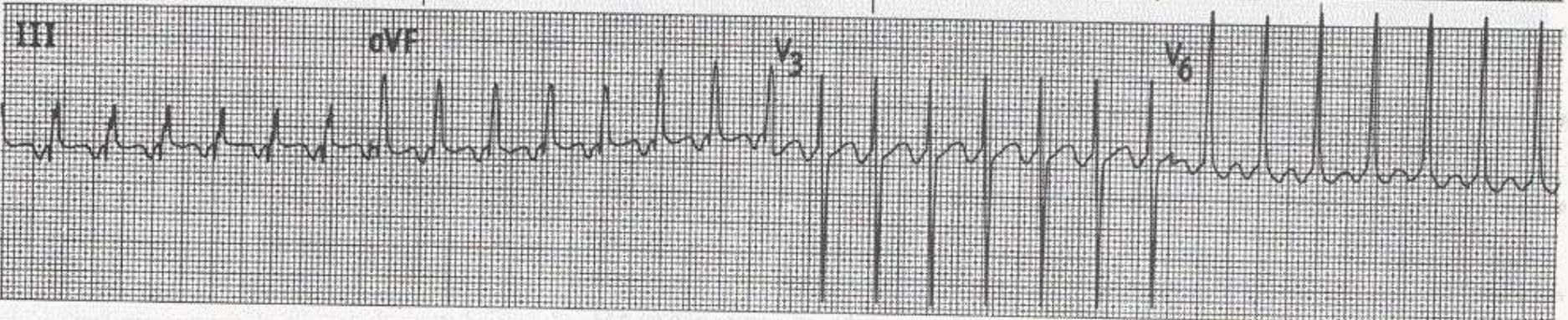
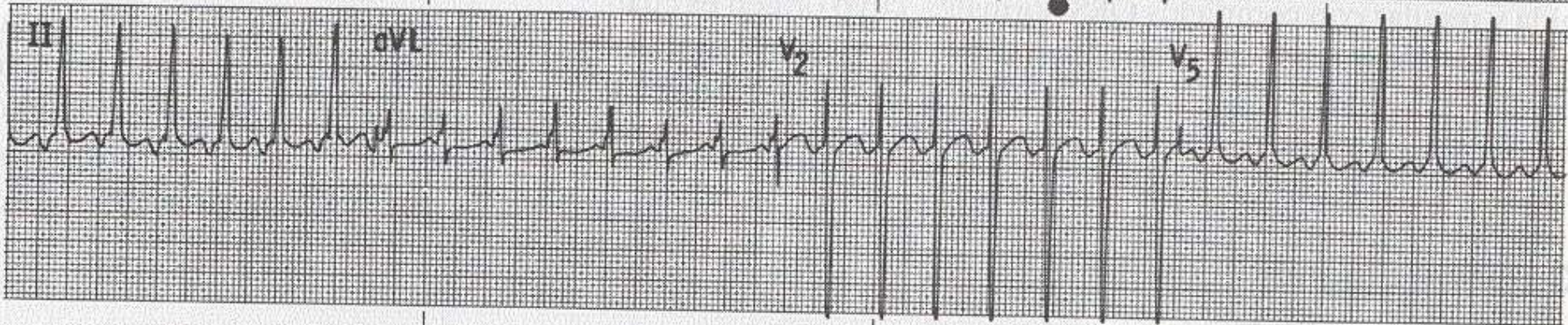
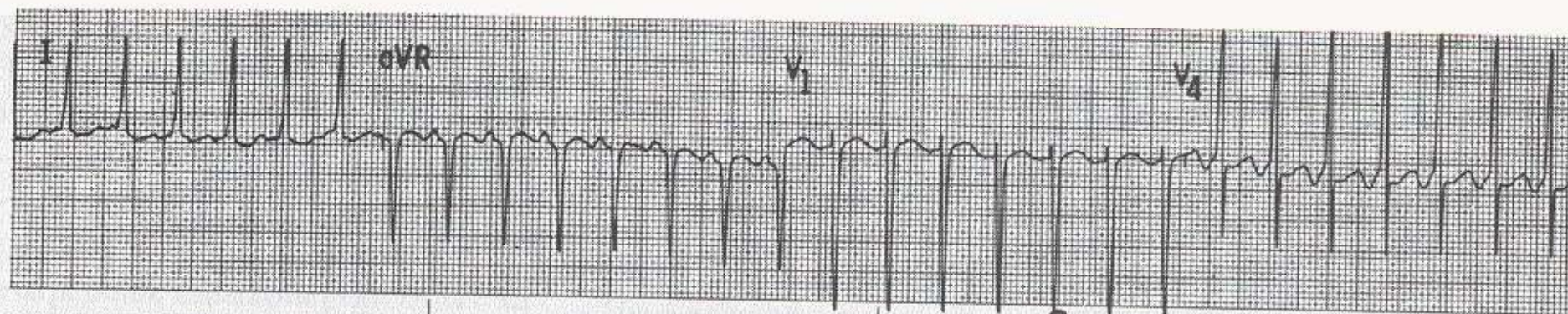


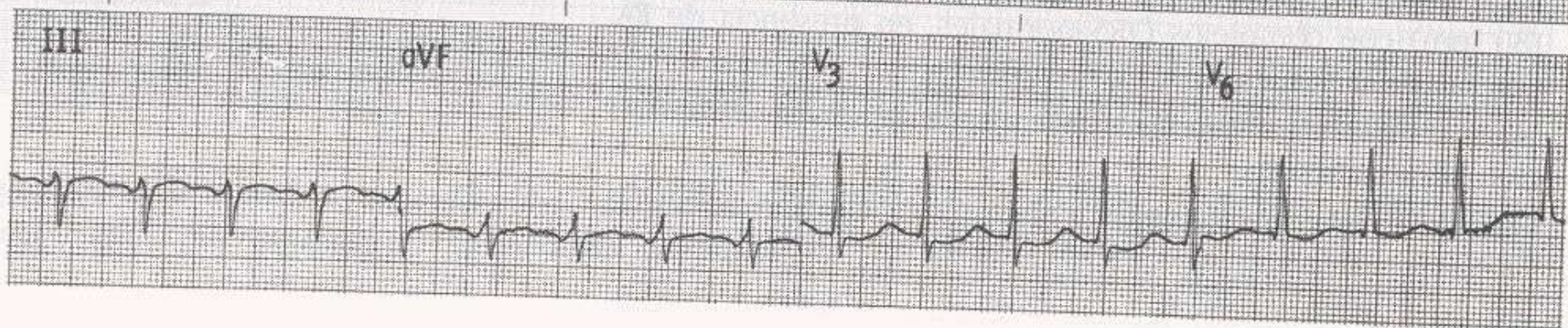
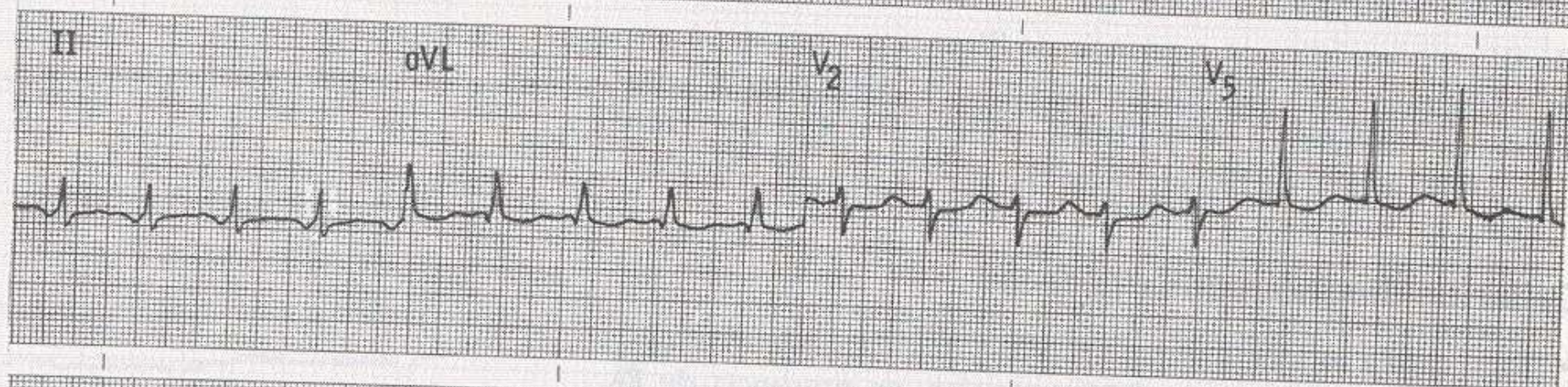
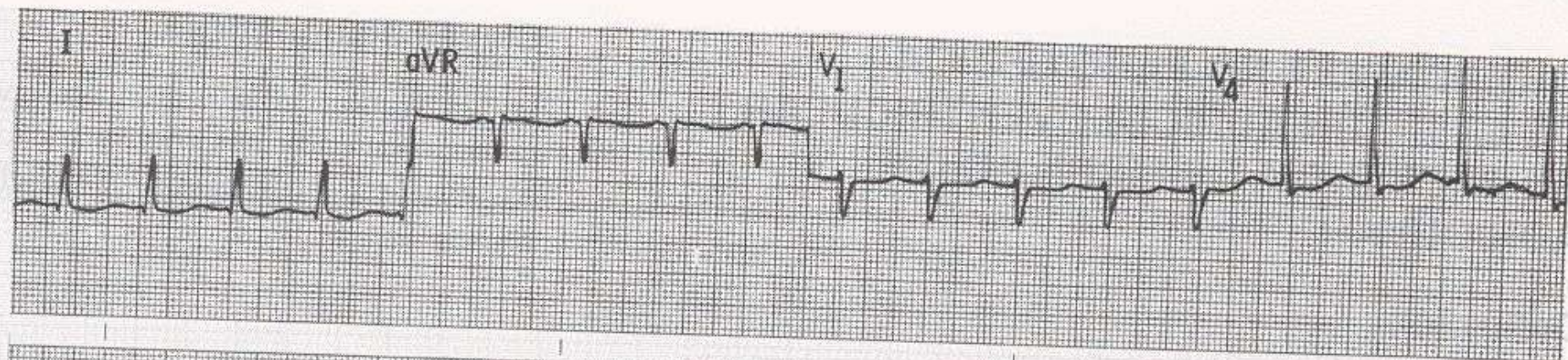
II

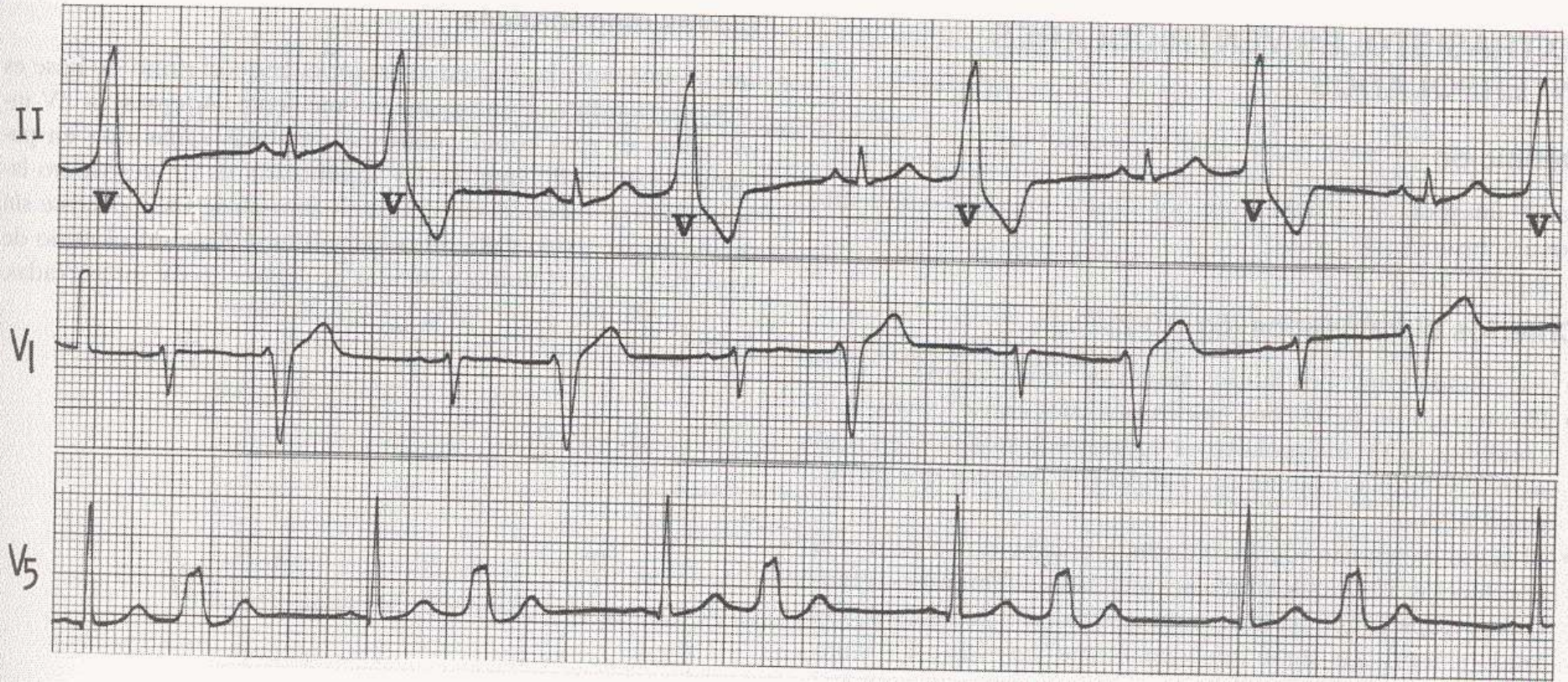


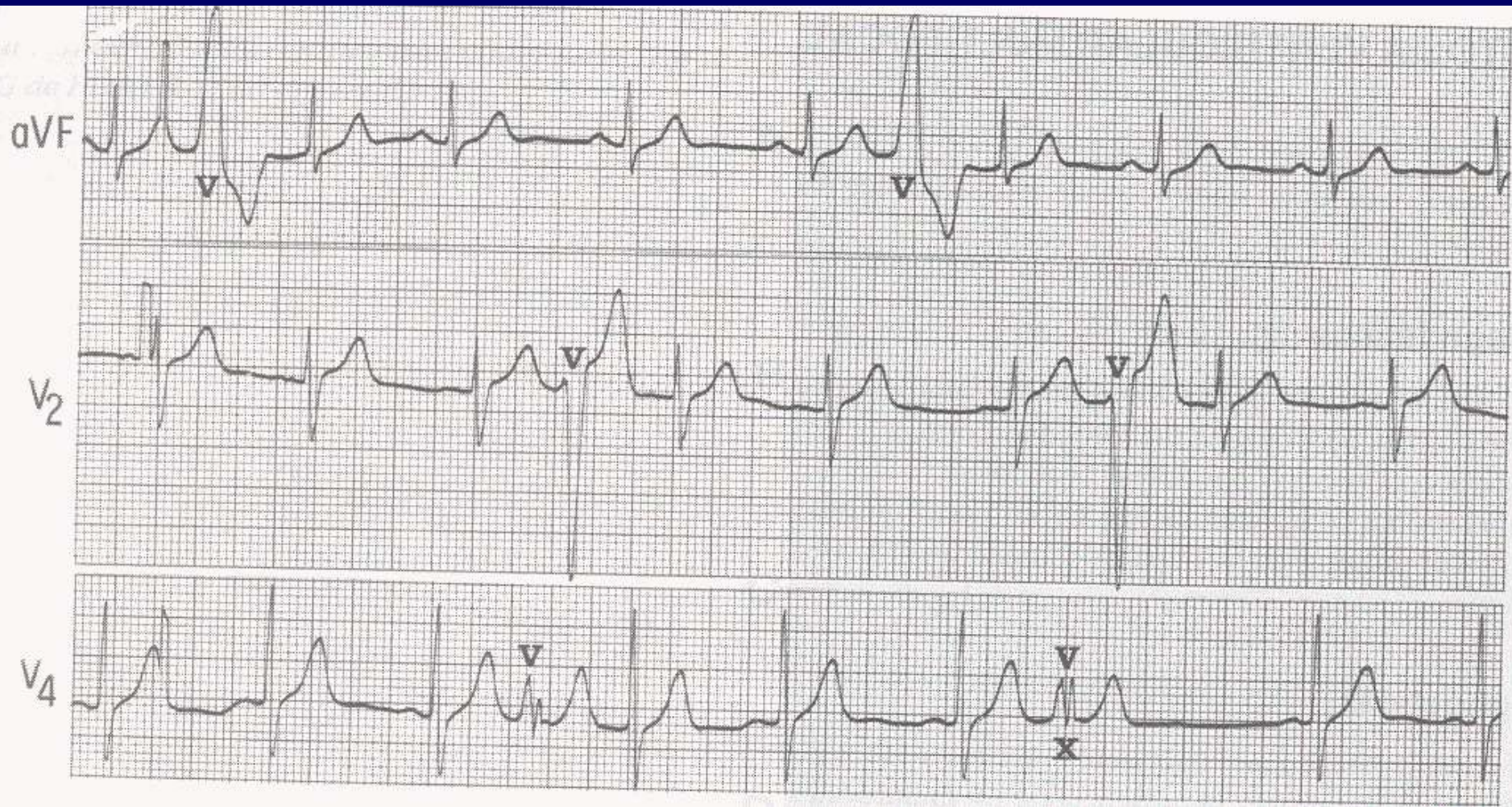
V₅

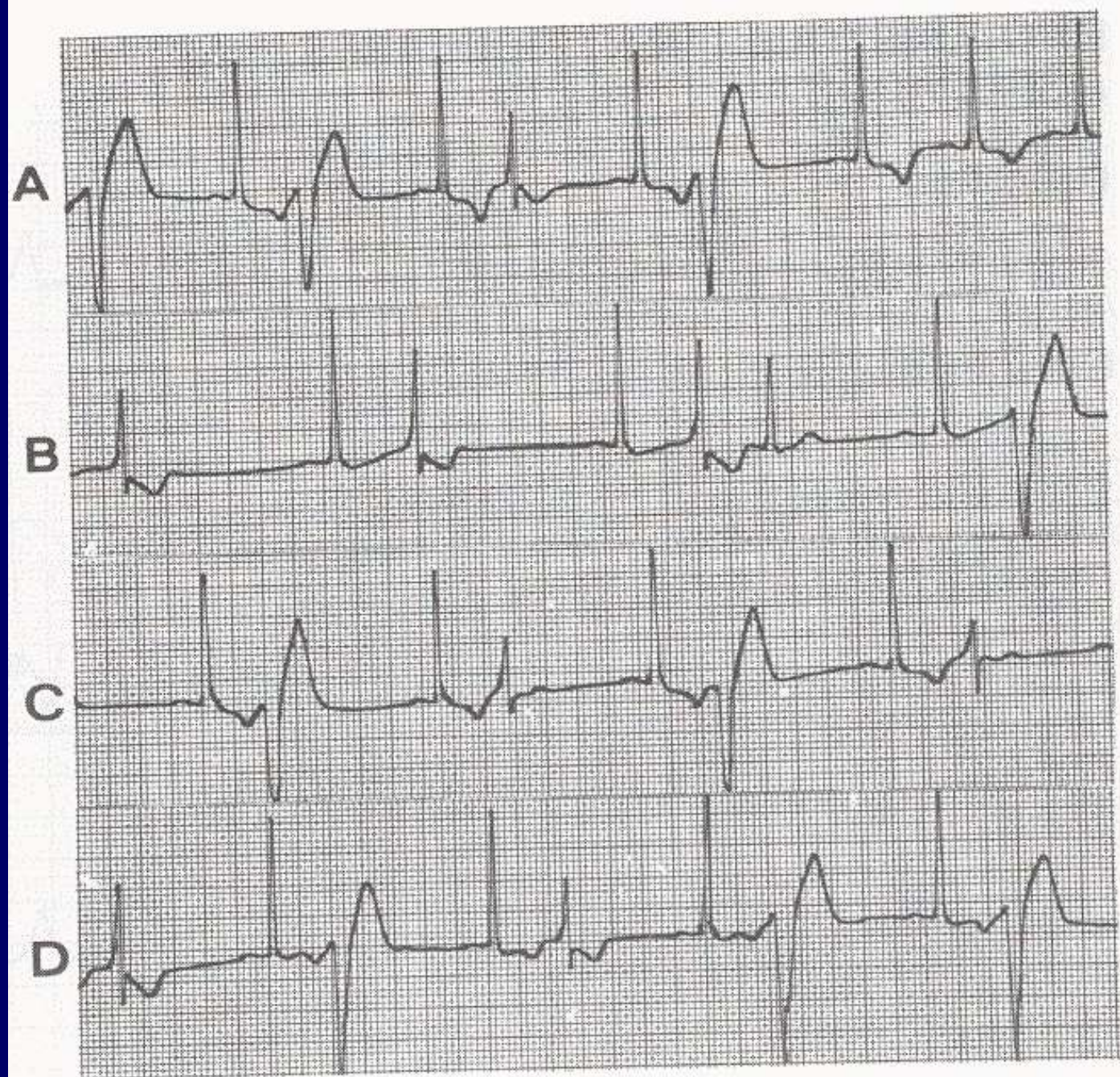




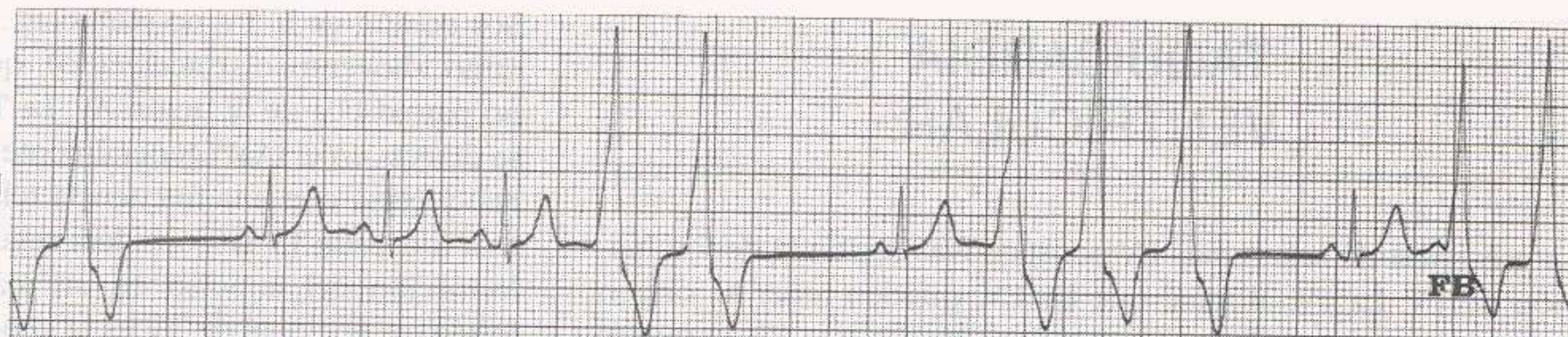




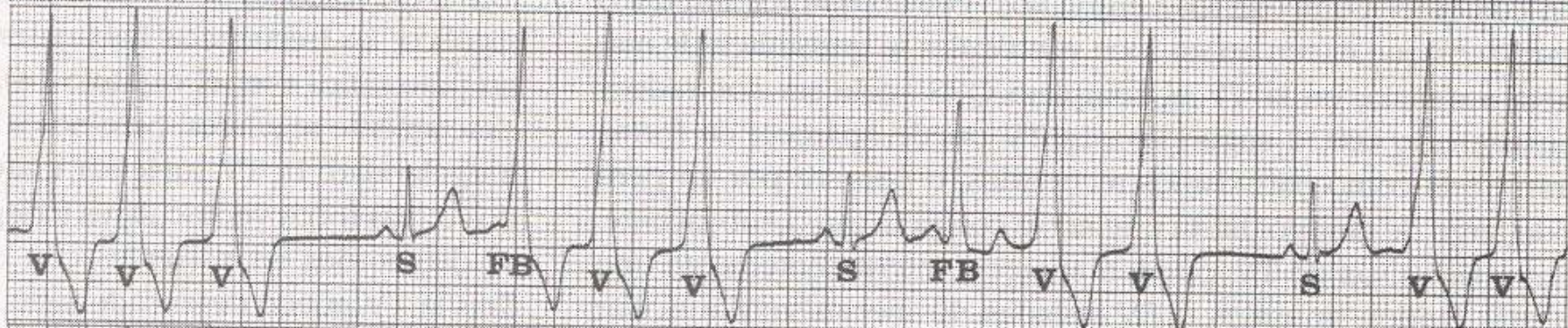




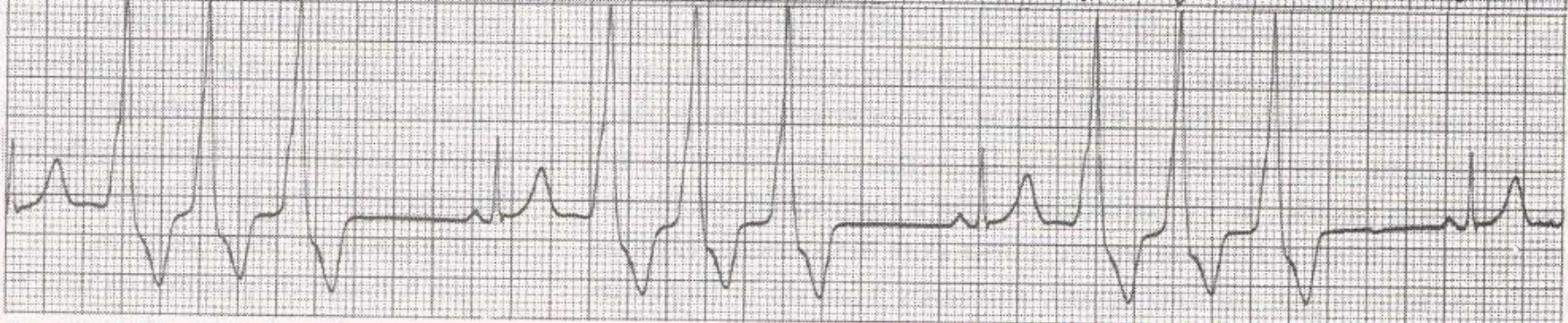
II-a

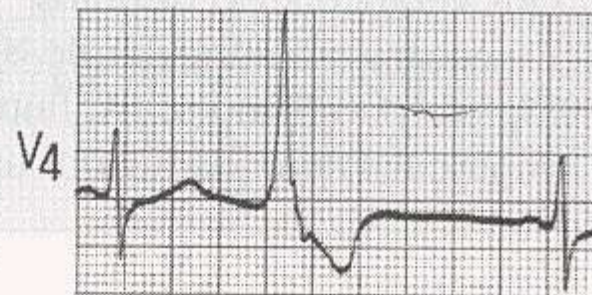
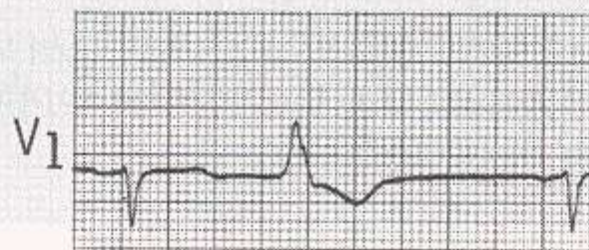
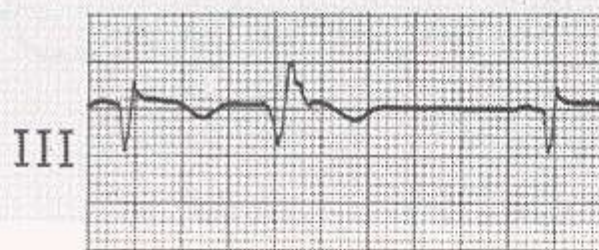
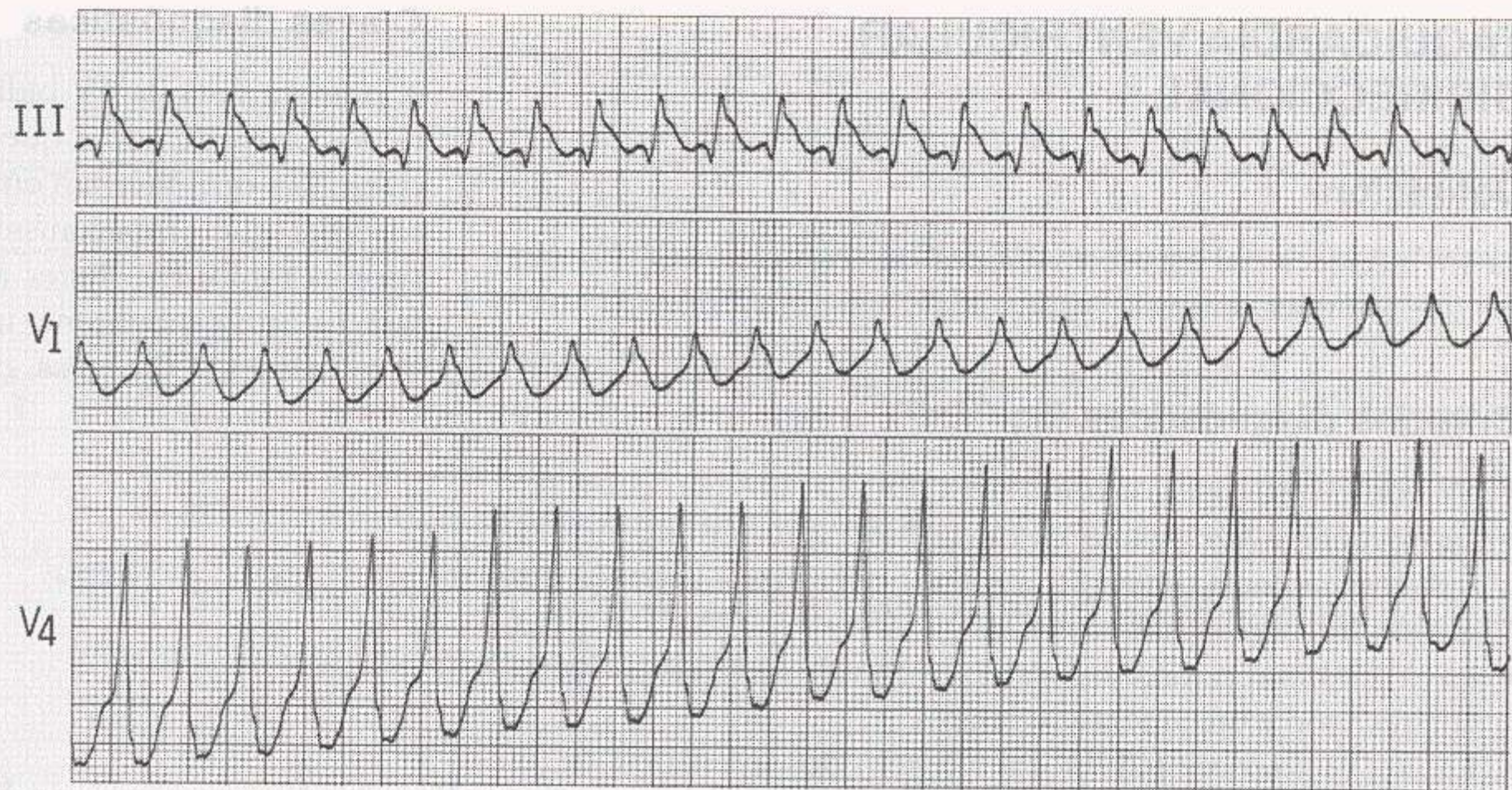


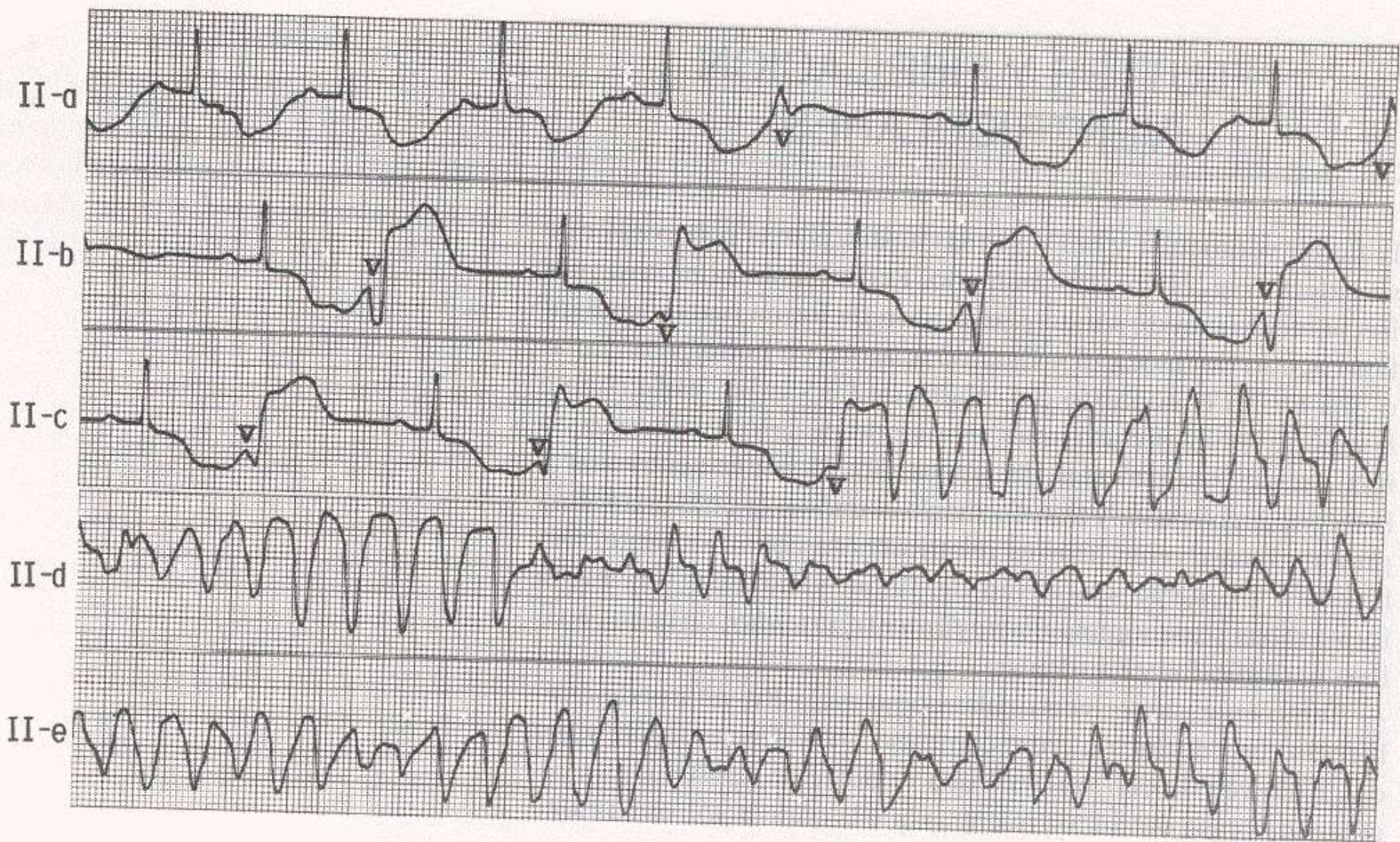
II-b

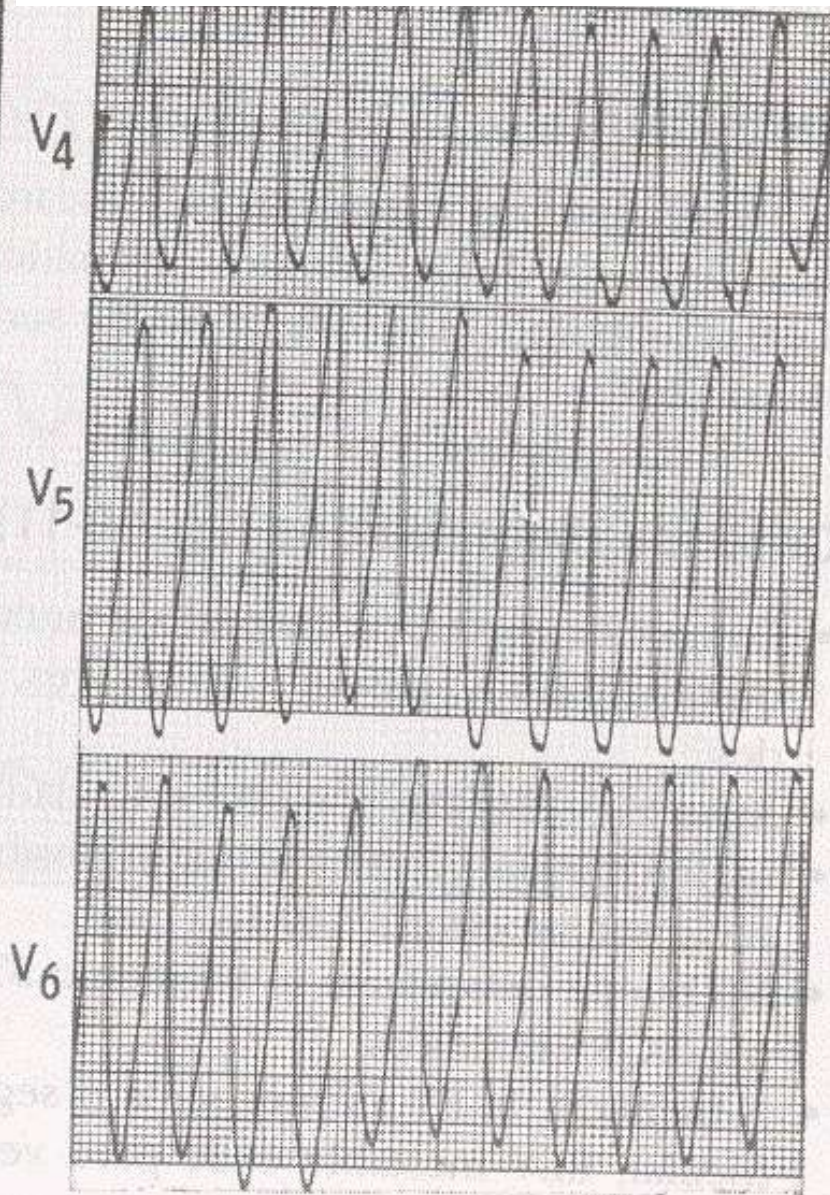
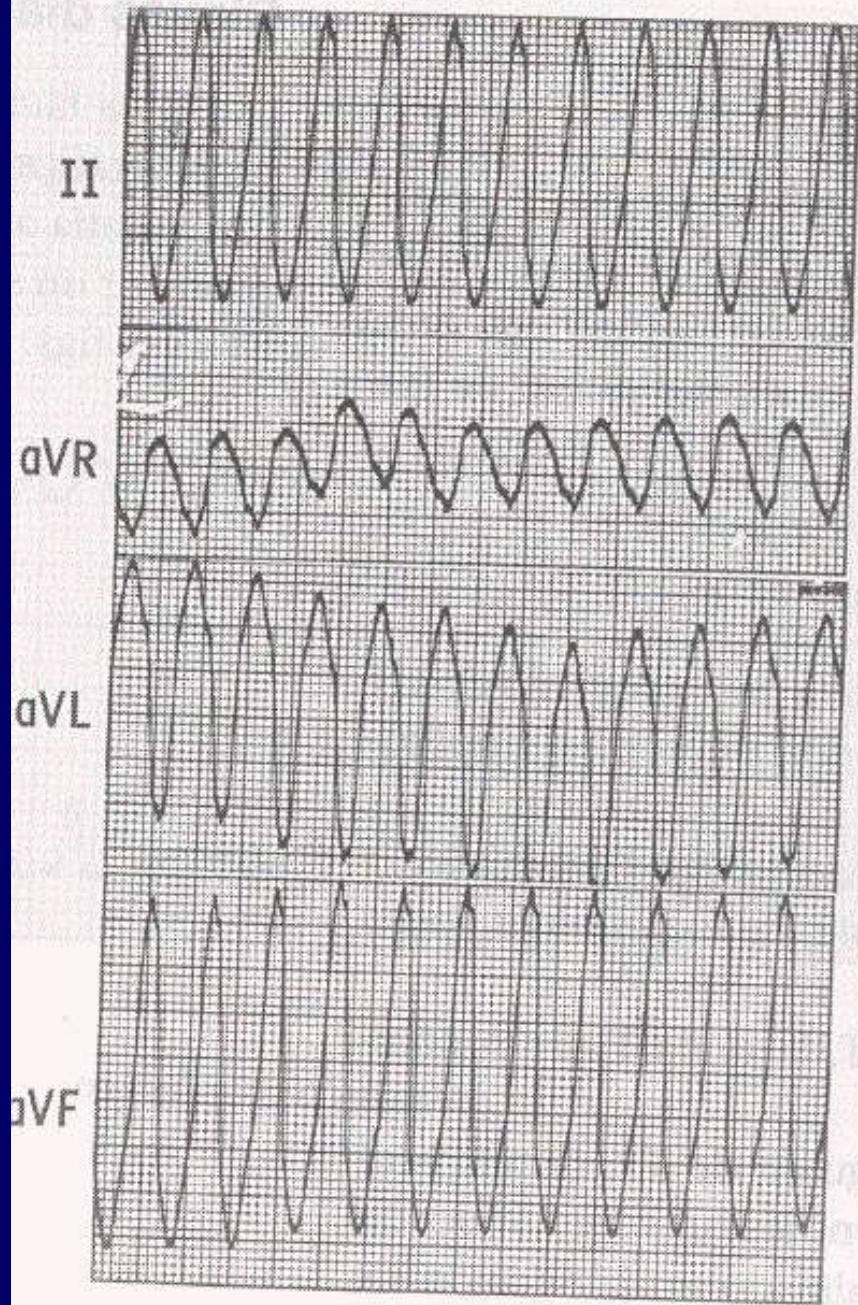


II-c





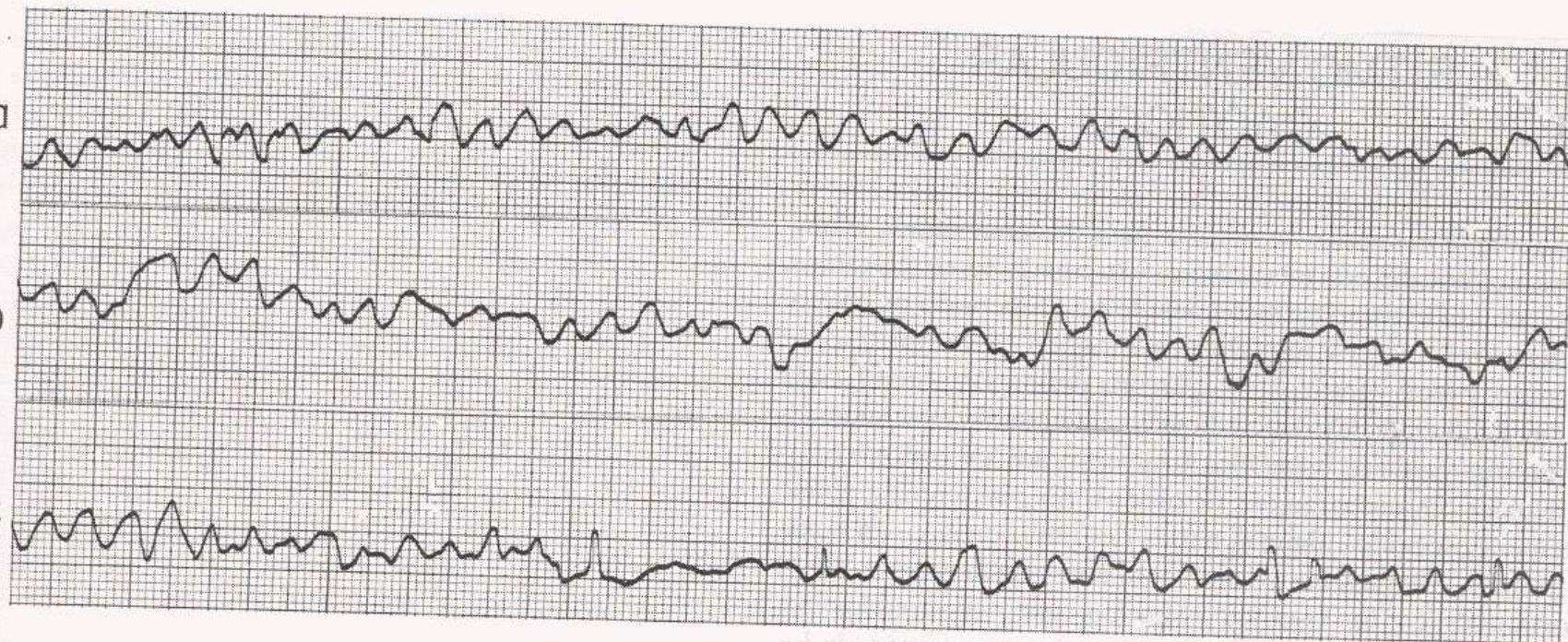


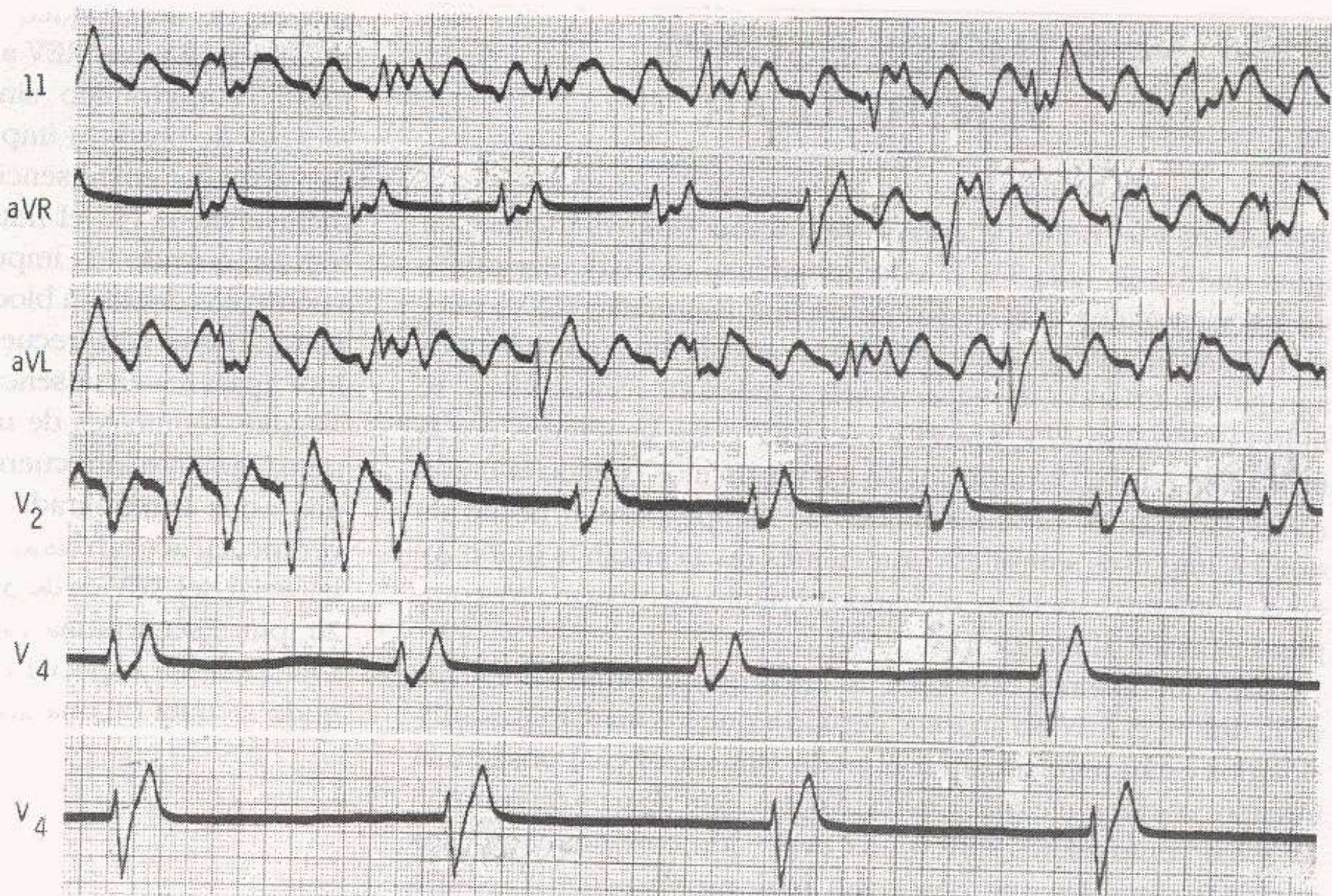


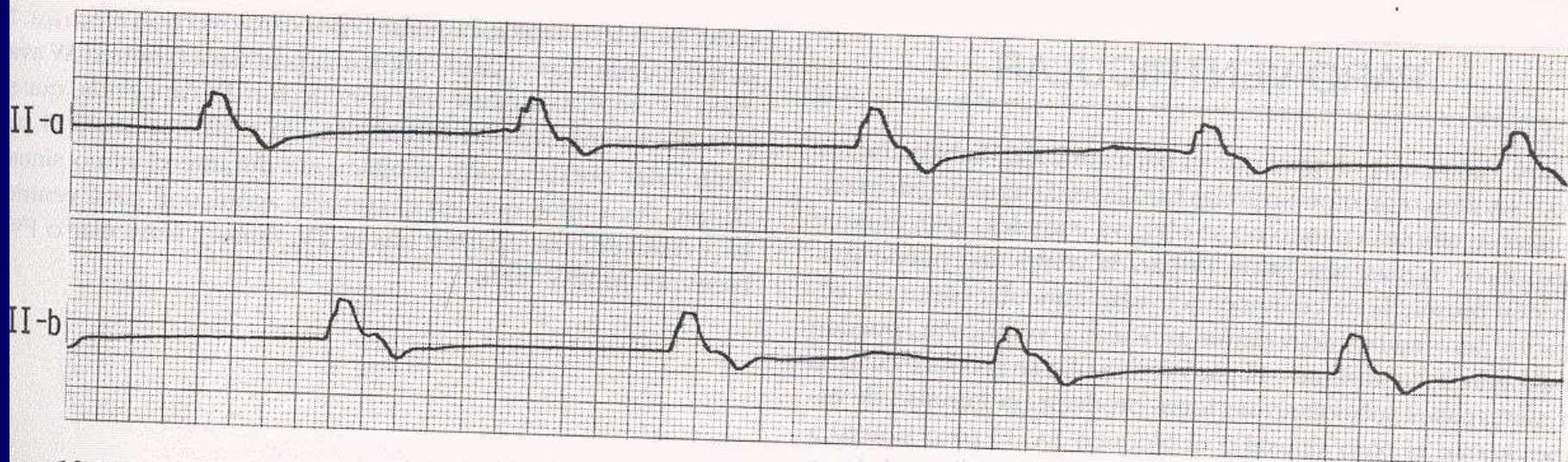
II-a

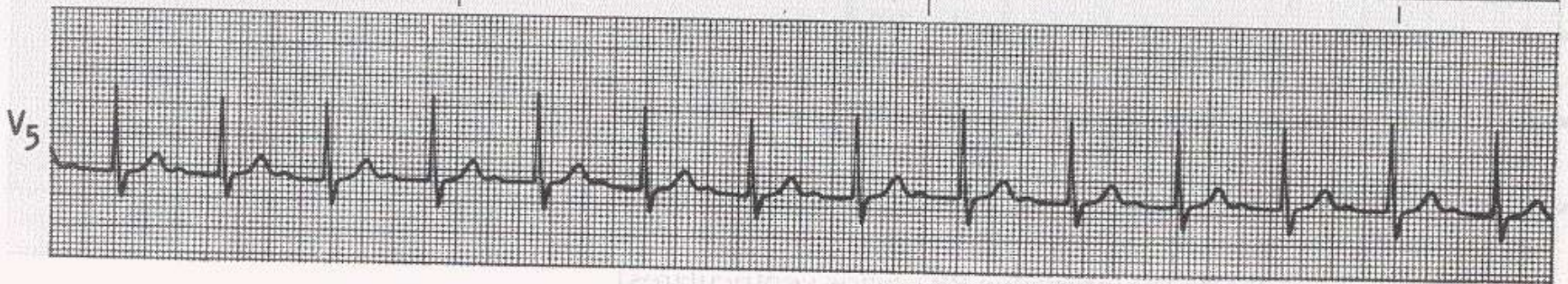
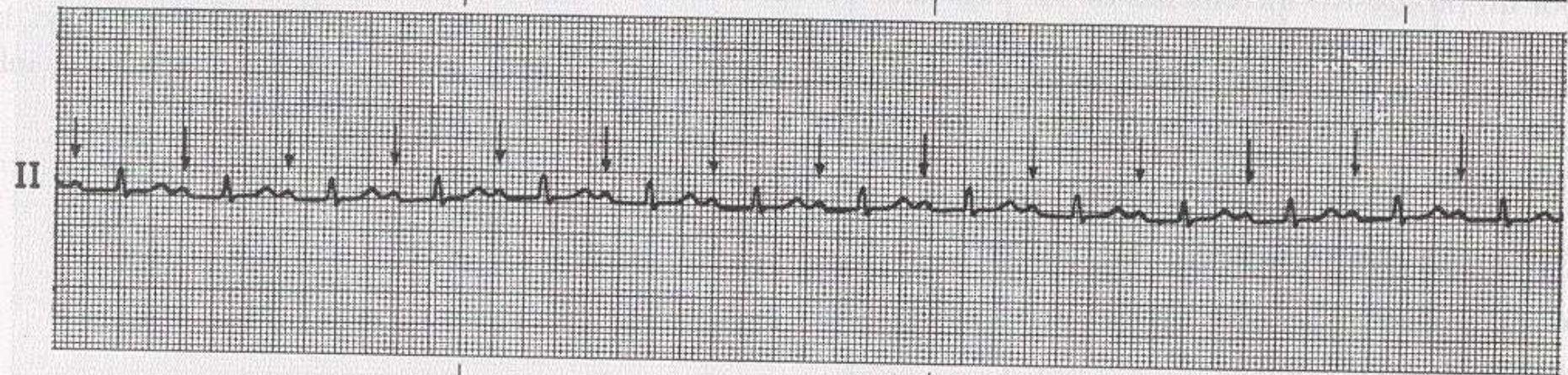
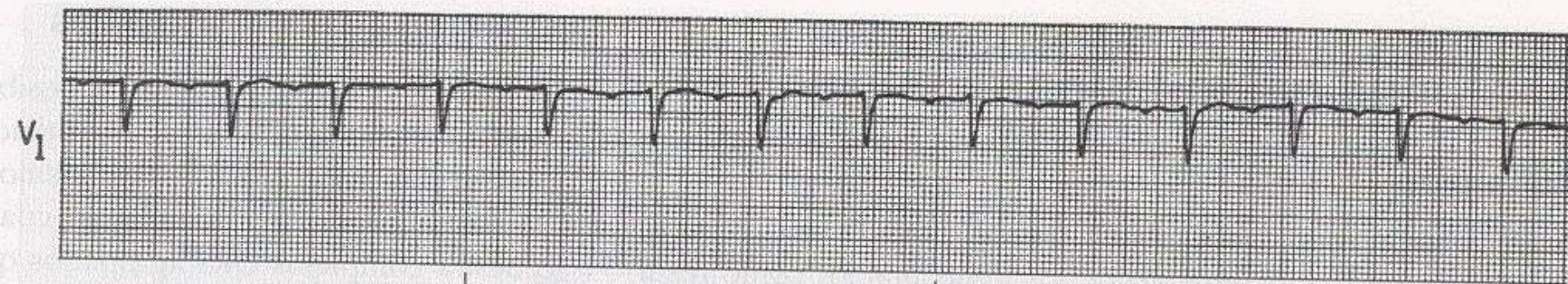
II-b

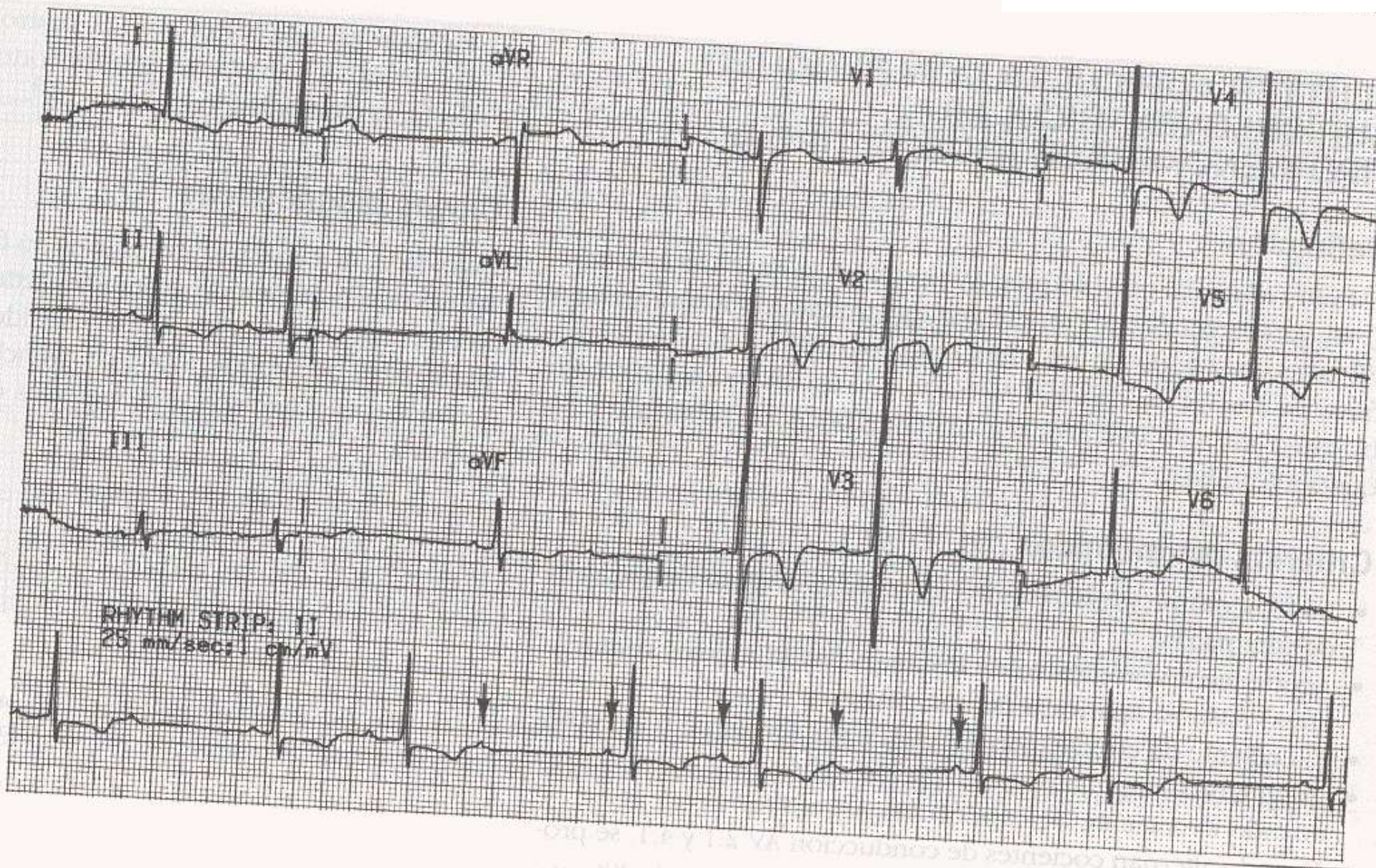
II-c

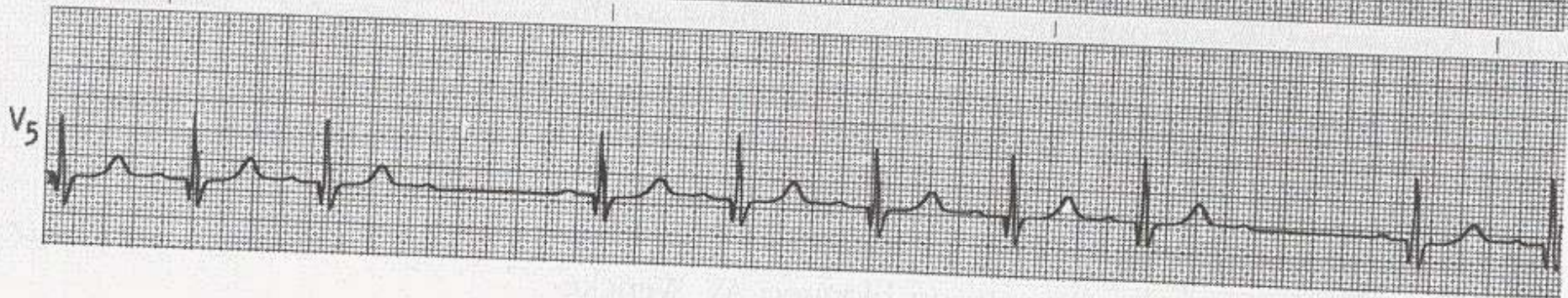
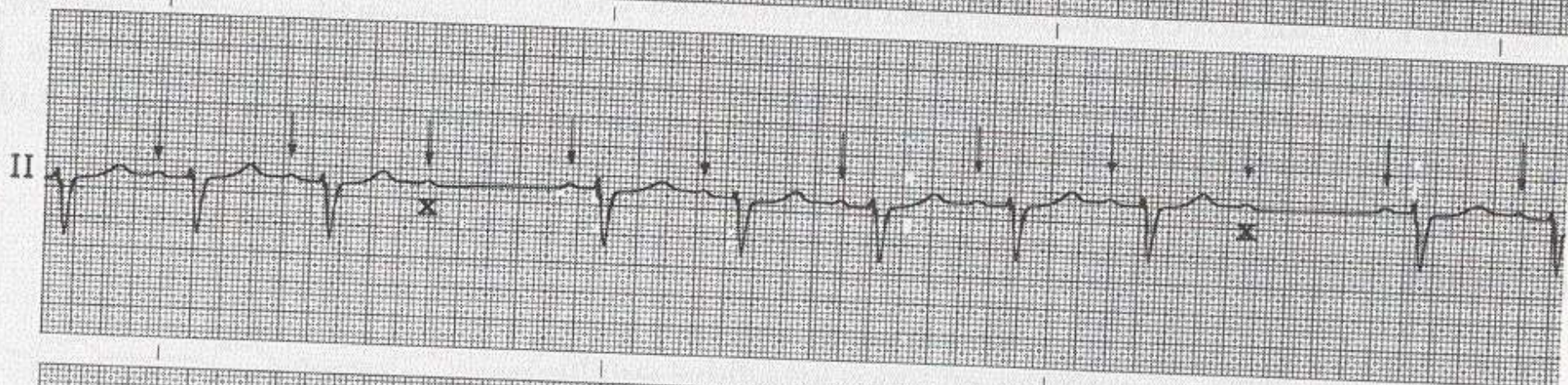
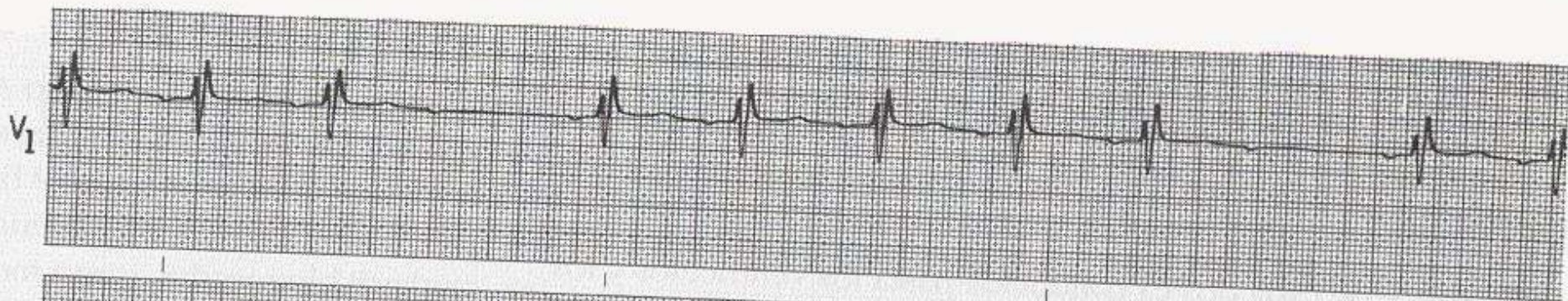


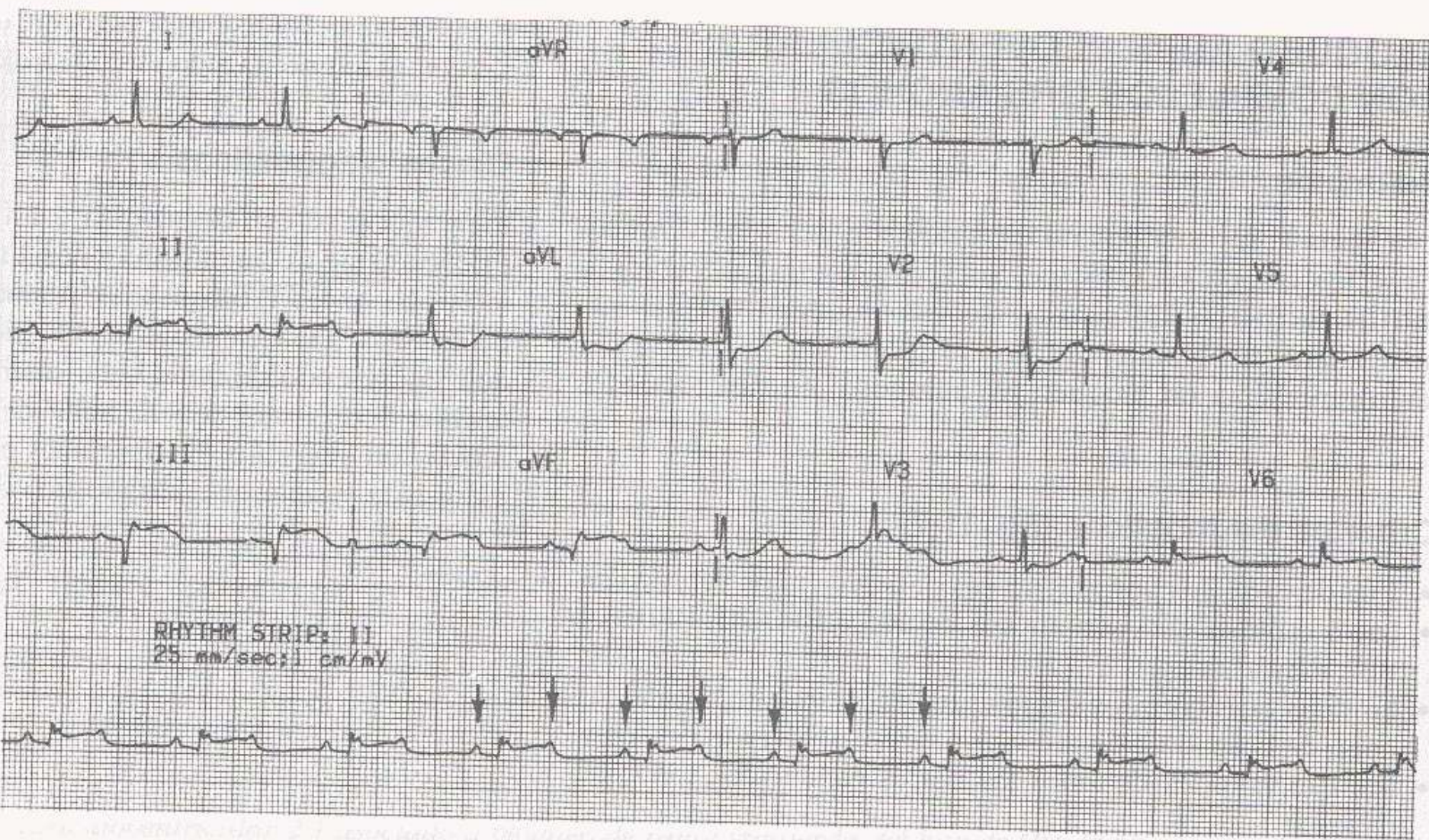


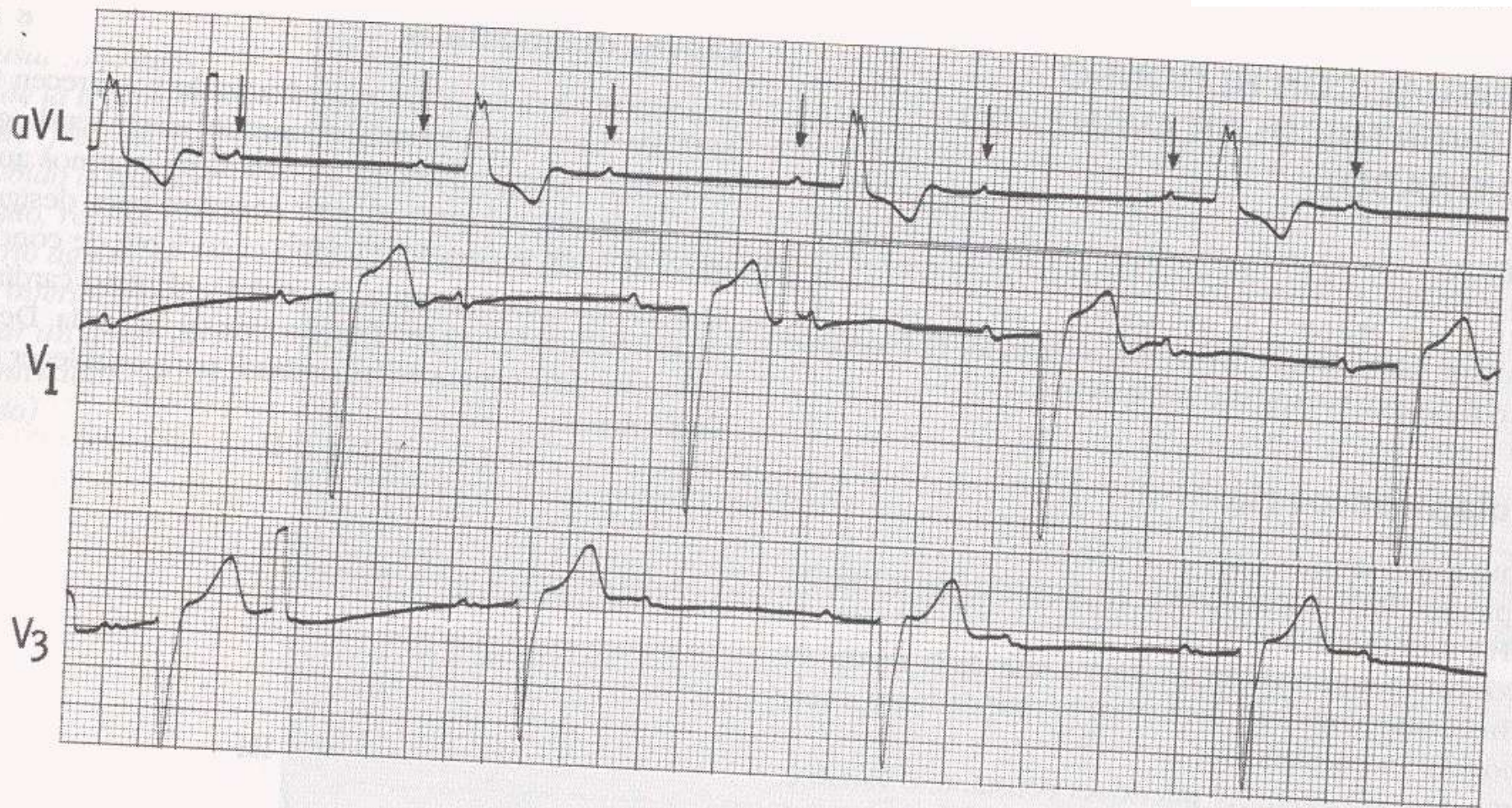


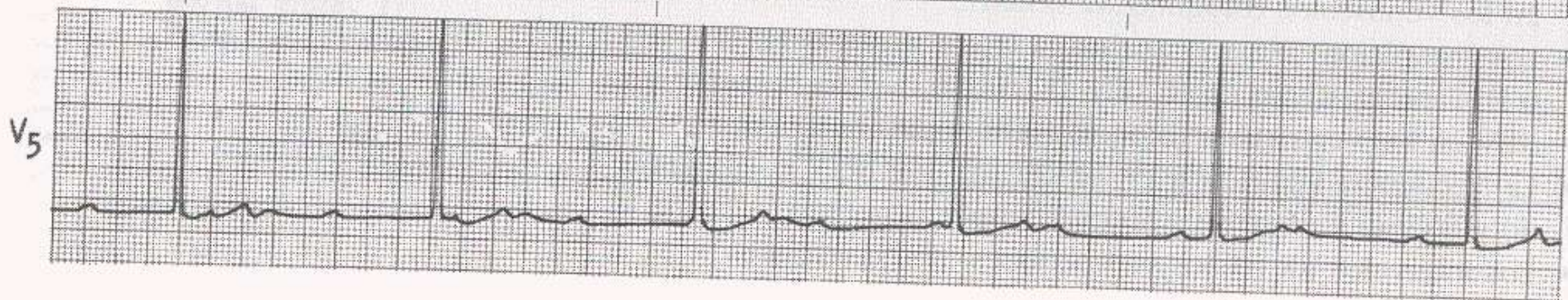
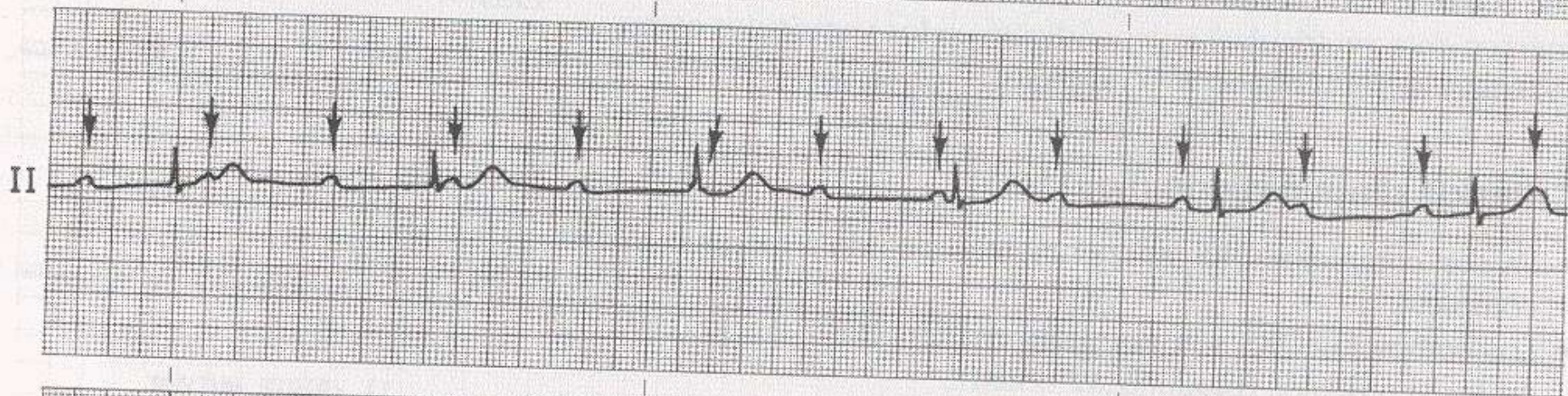
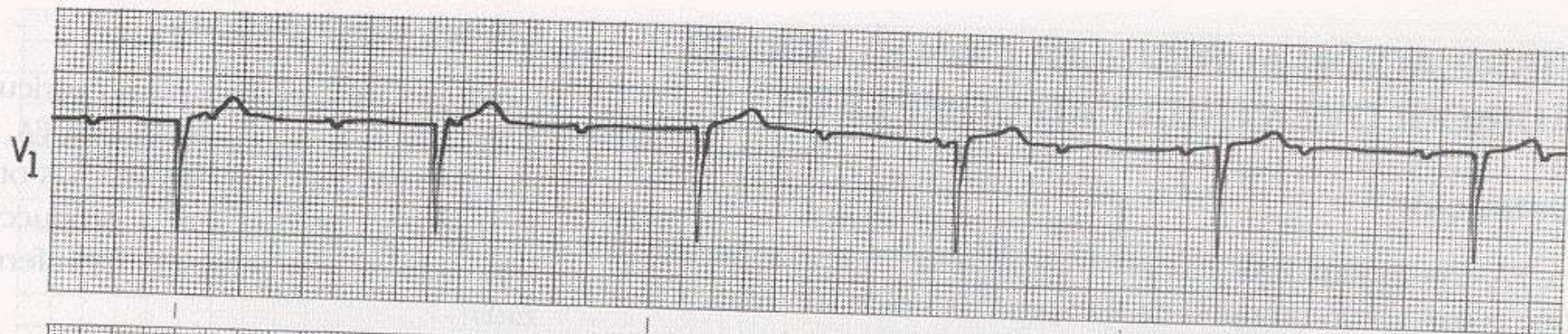


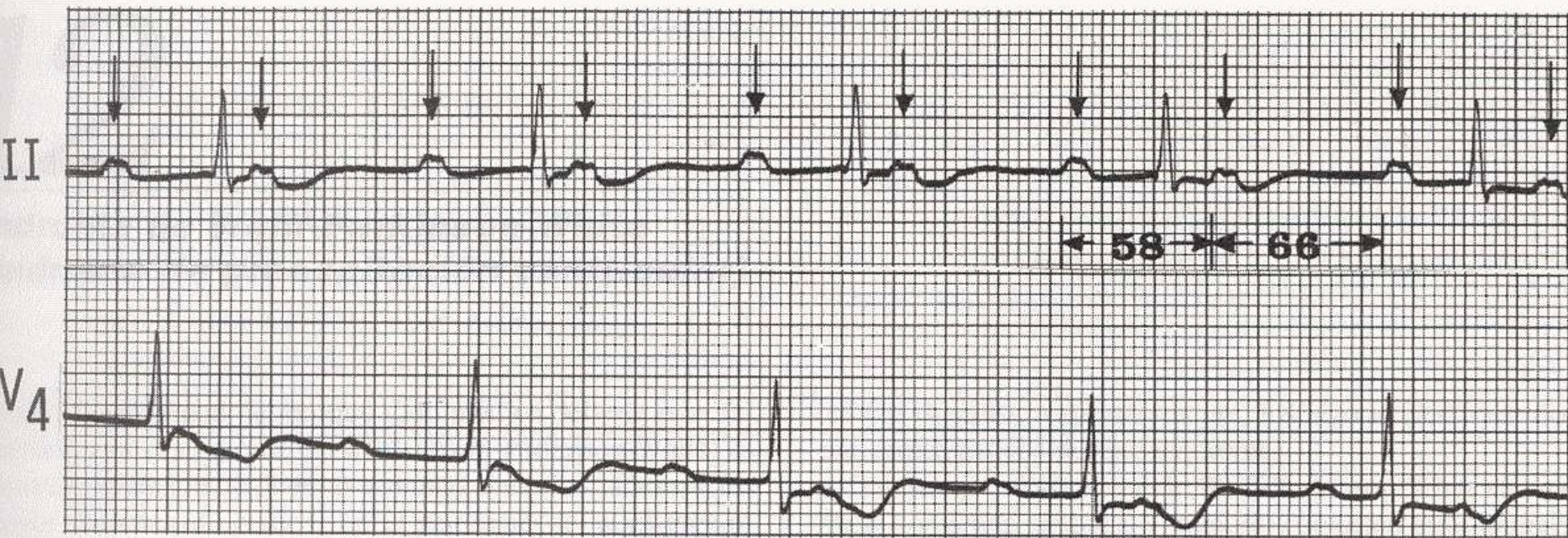


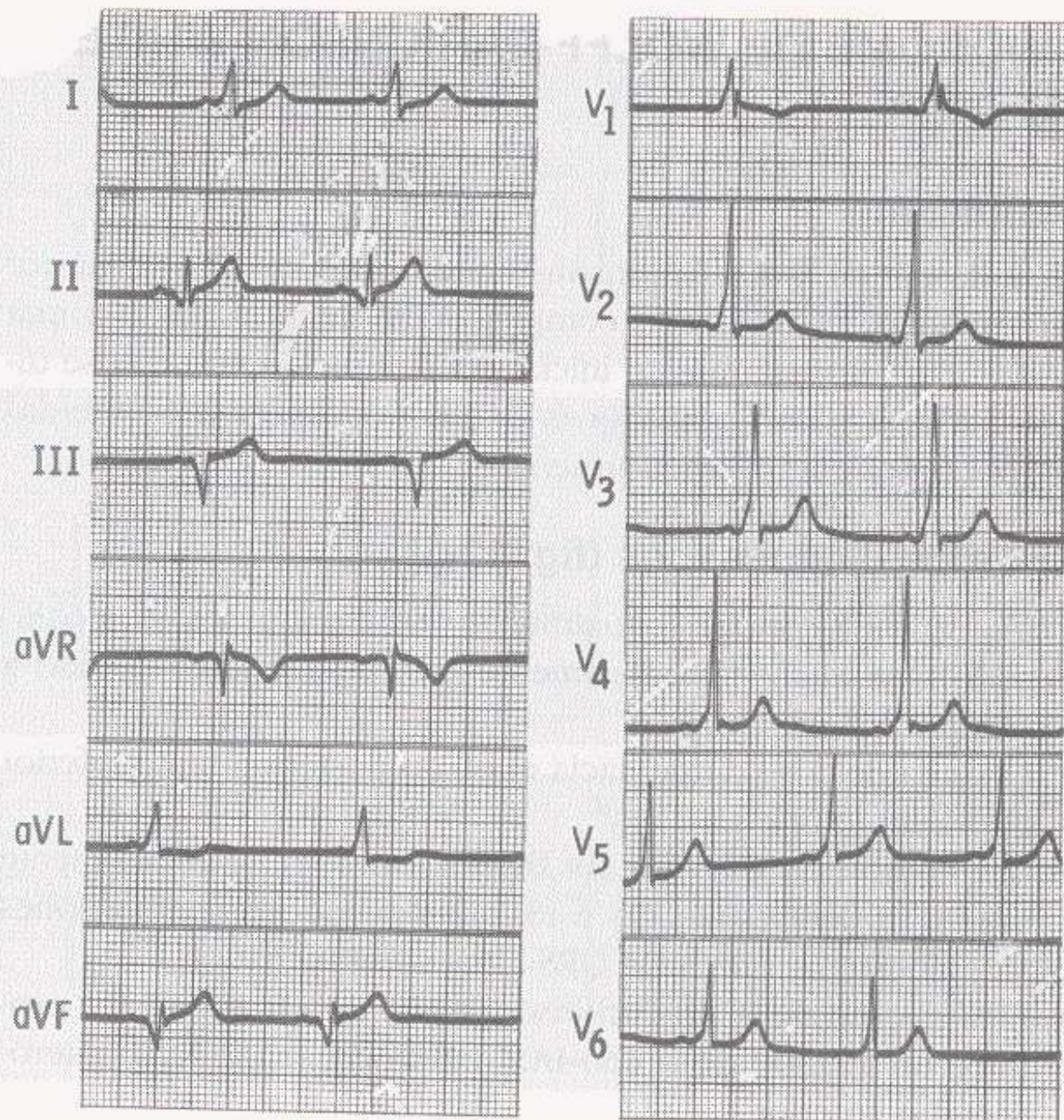


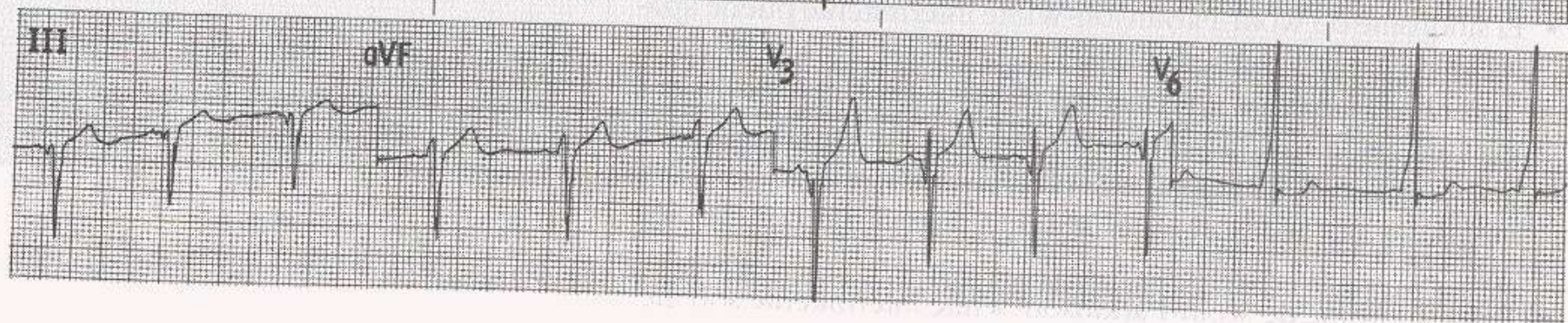
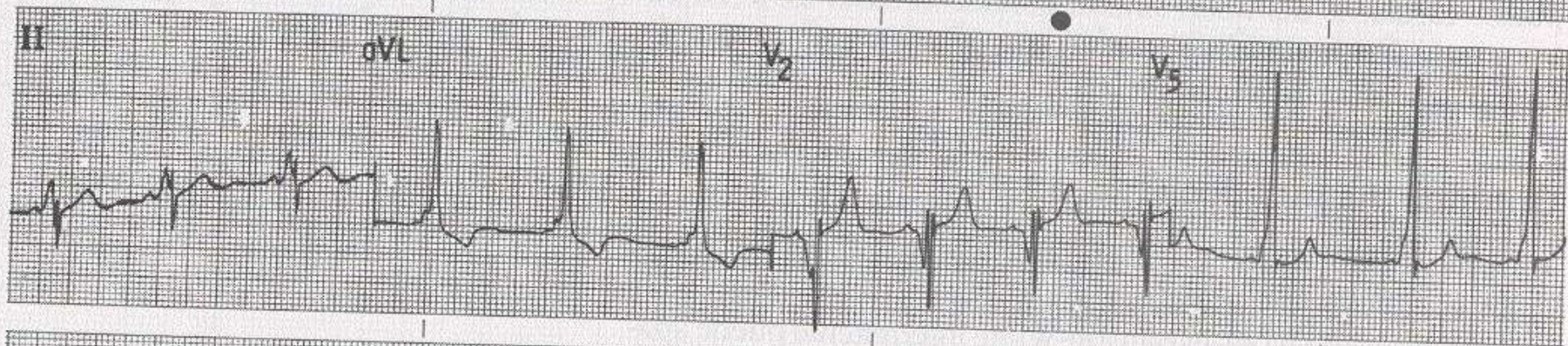
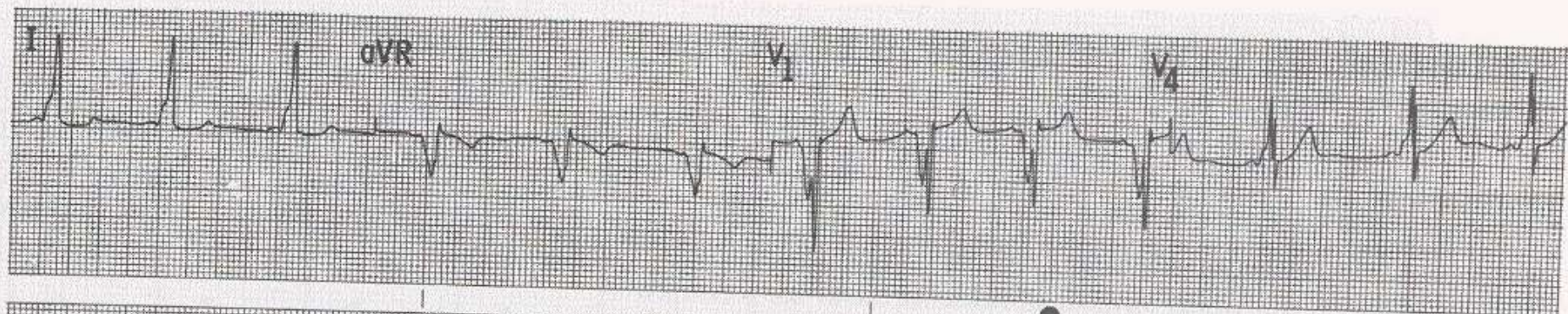


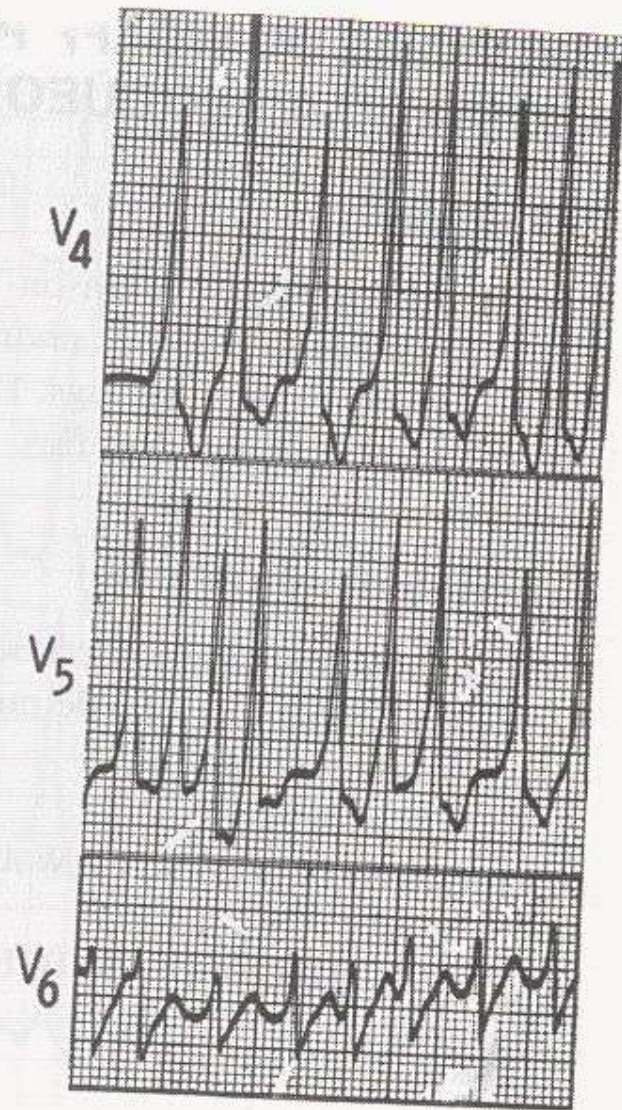
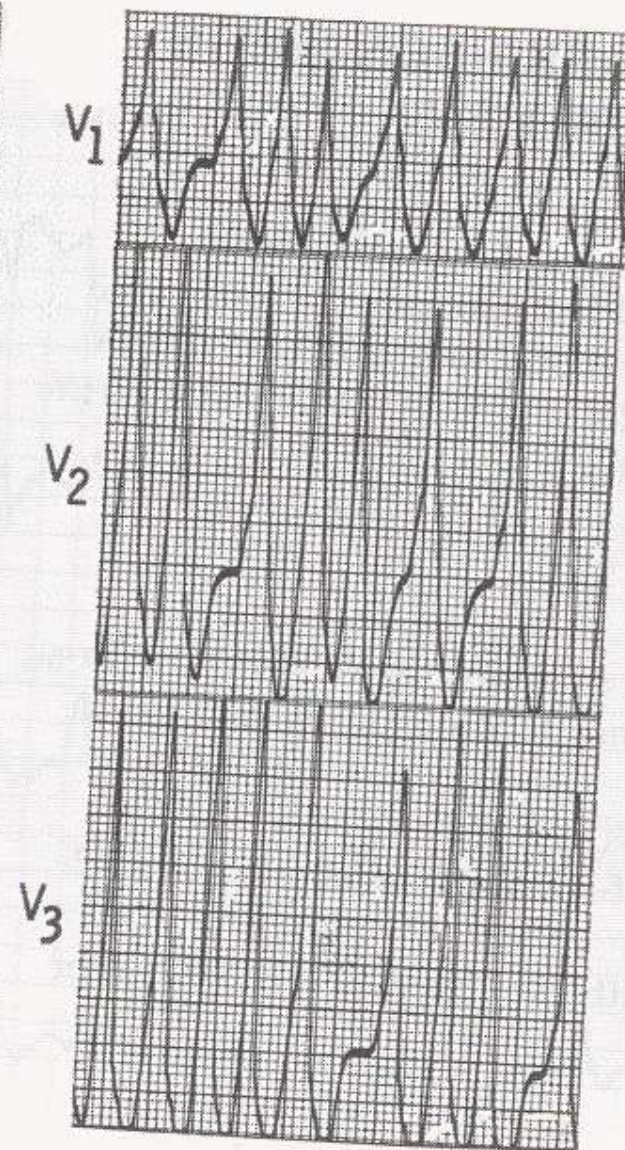
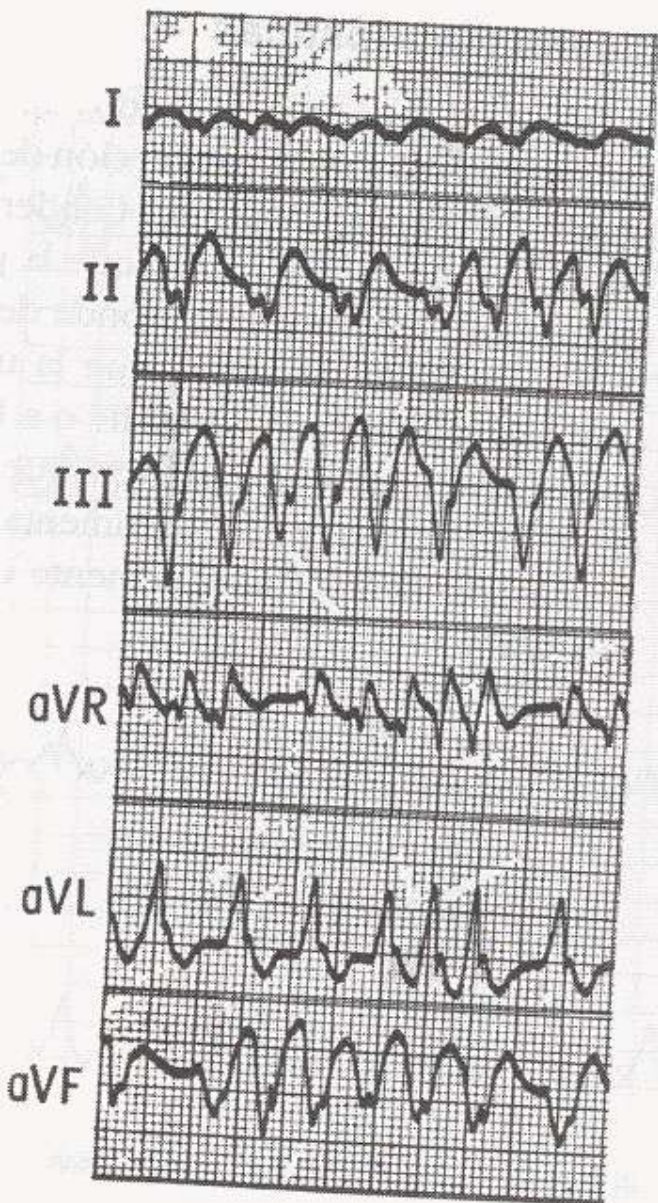


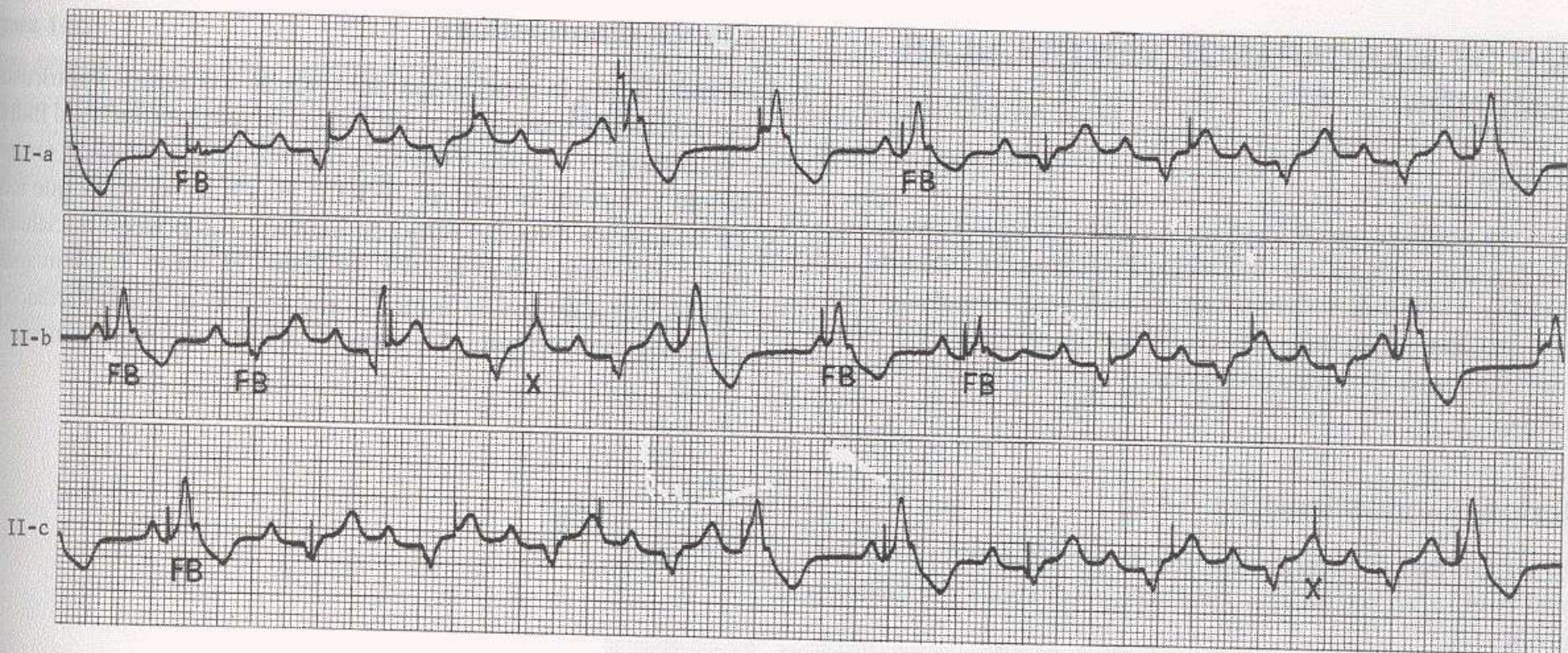




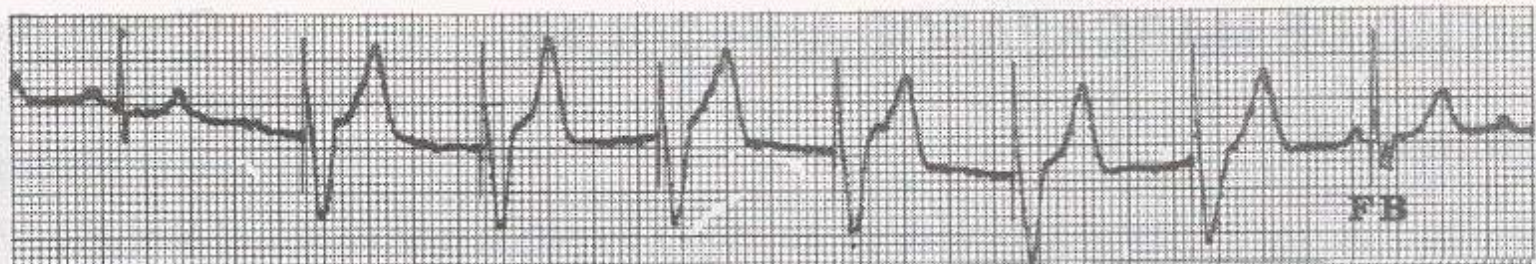




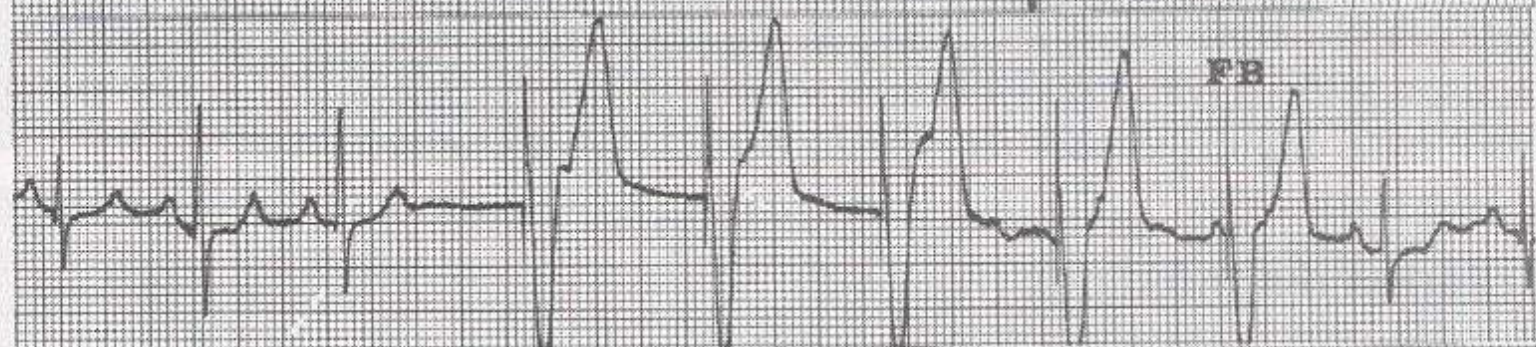



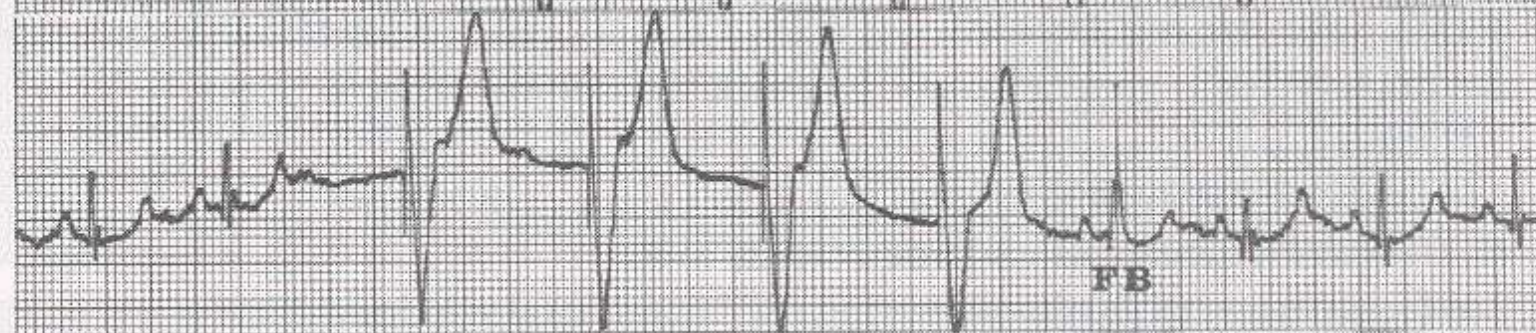A



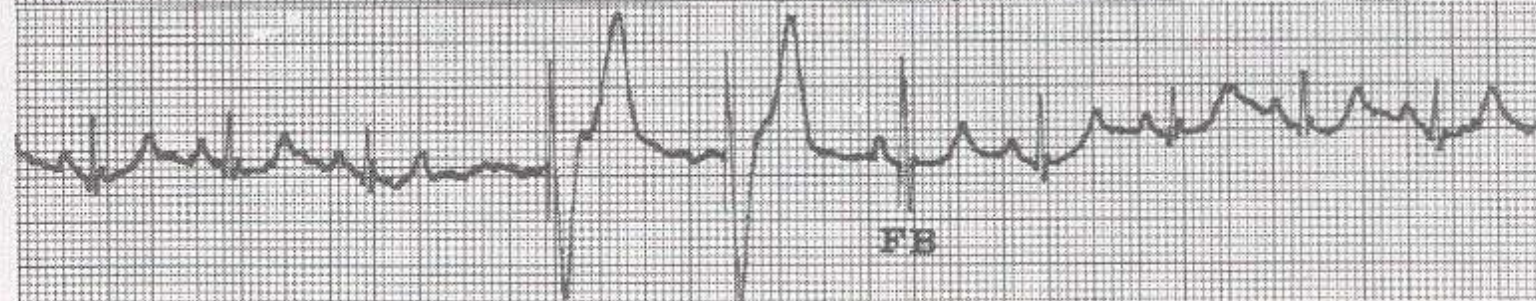
B

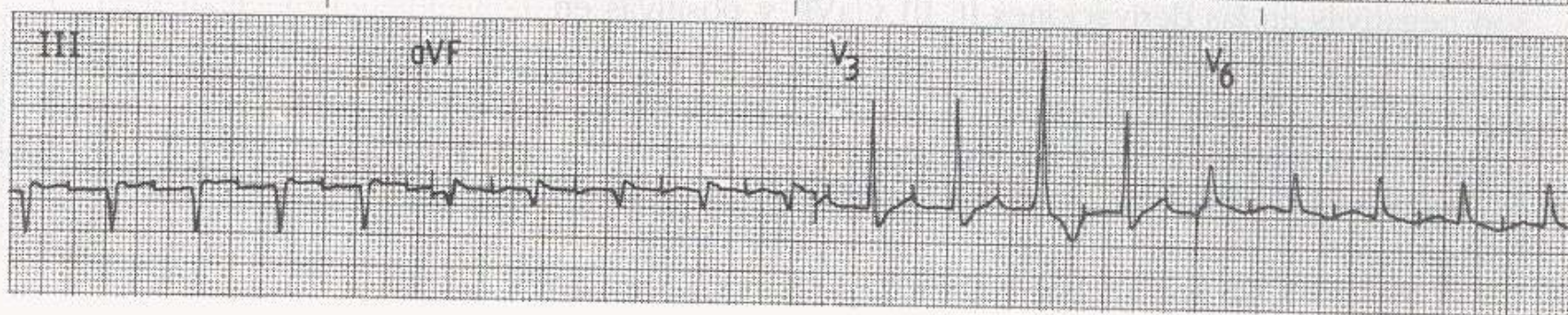
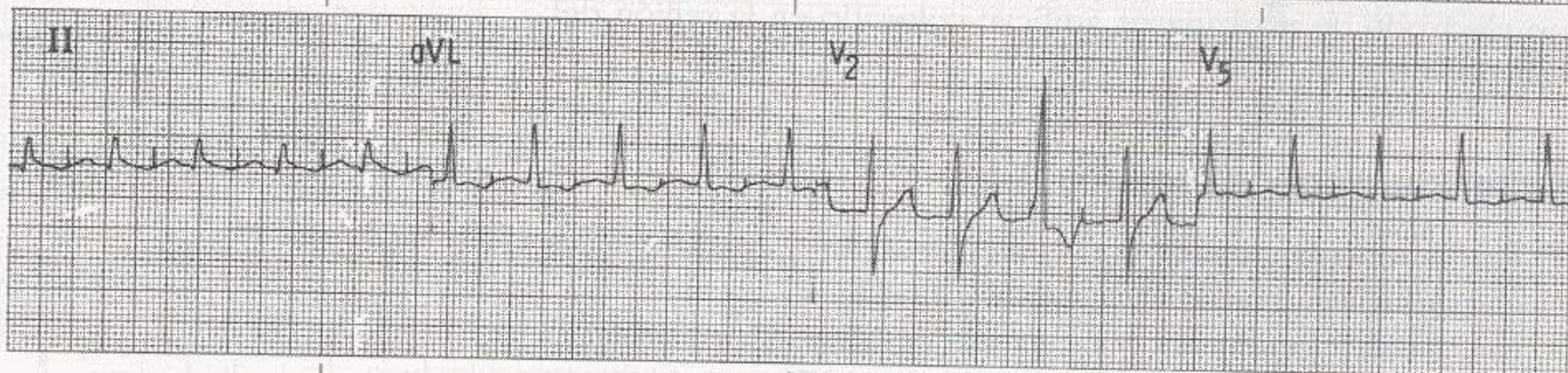
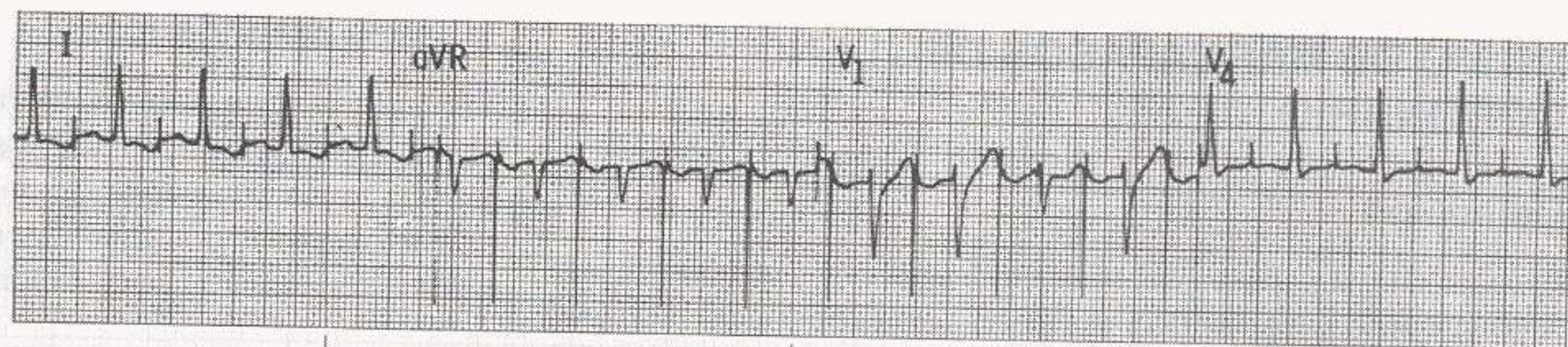


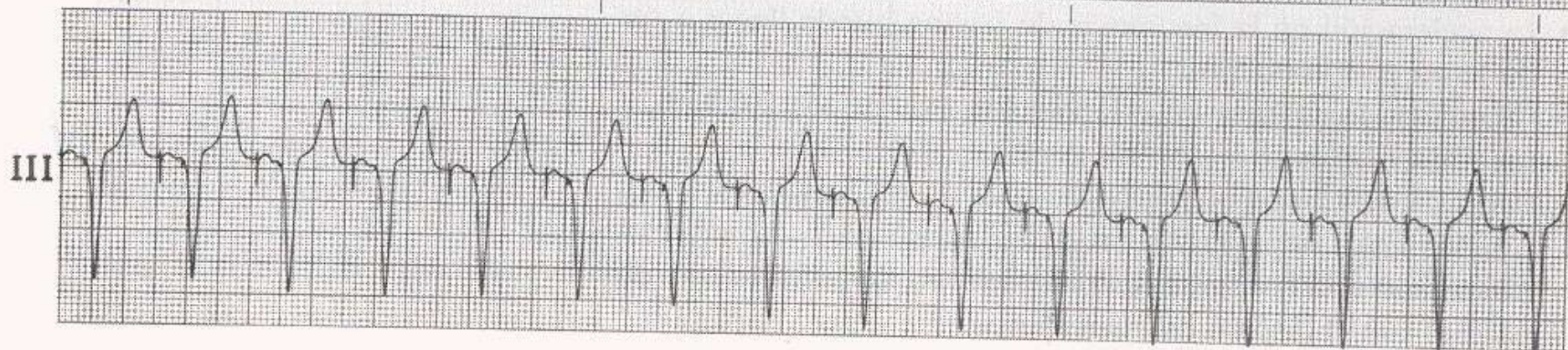
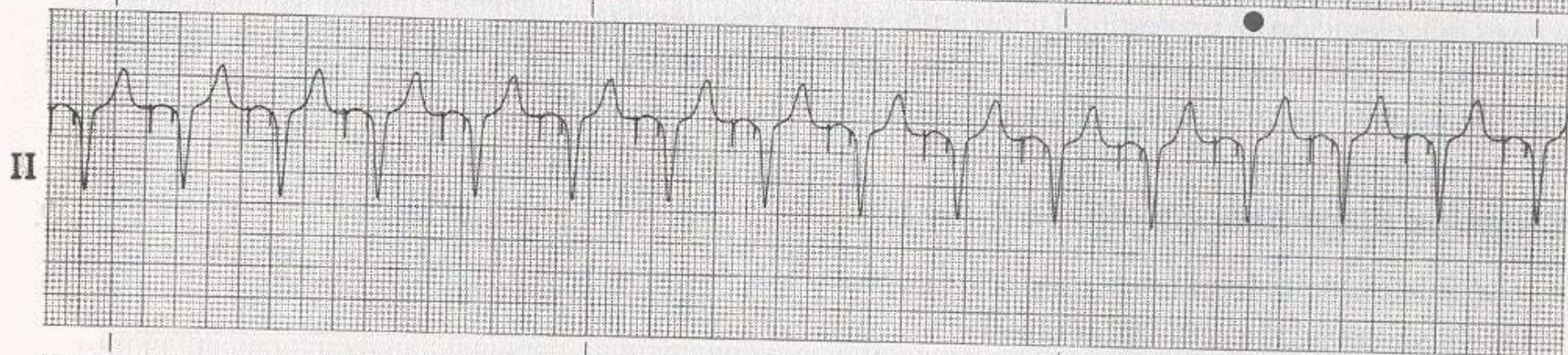
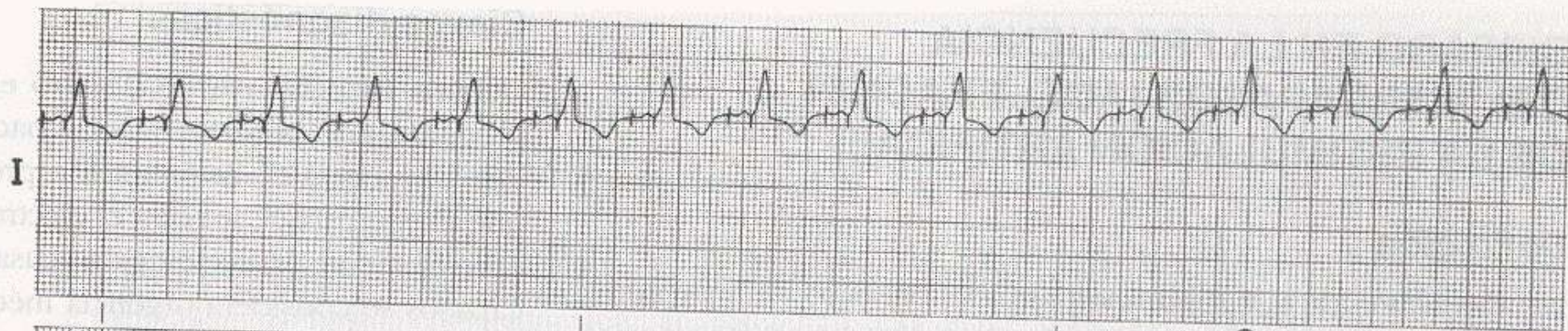
C



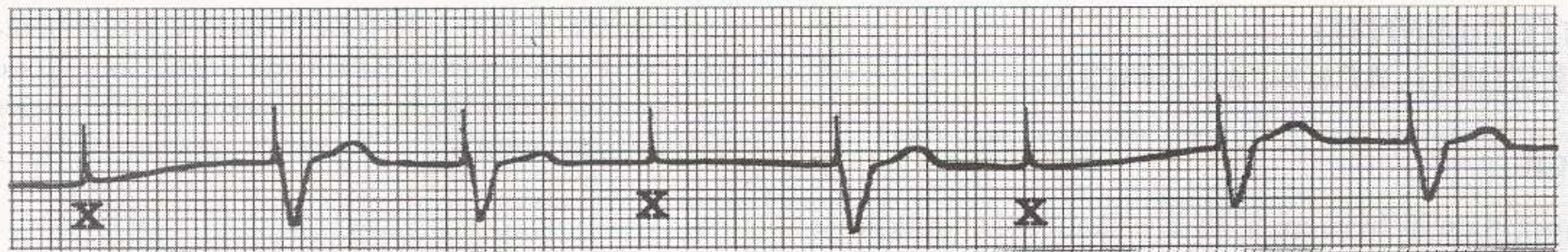
D



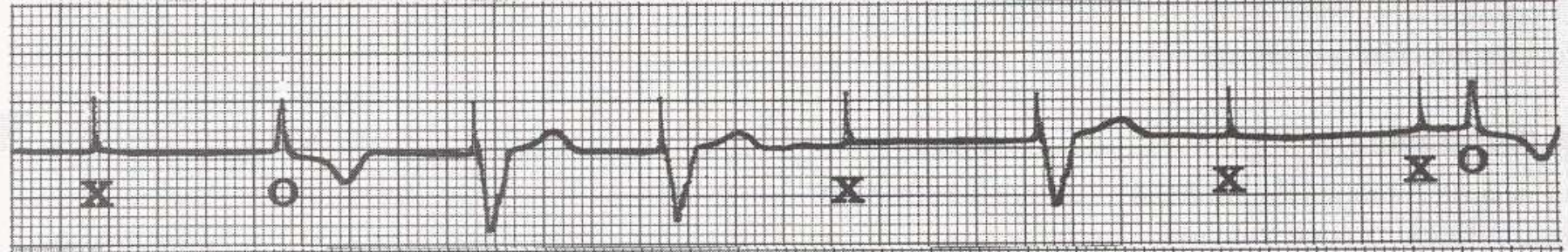




A



B



C

